

Research Article

Open Access

New Concept of the Development of Brainstem Ischemia in the Setting of Occlusions of the Vertebral Arteries and Radicular and Medullary Arteries in the Presence of the Cervical Spinal Injury

Mykola Salkov^{1*}, Natalia Zozylia², Vitaliy Tsymbaliuk³, Lydmila Dzyak⁴, Sergey Kozlov⁵, German Titov⁶ and Margaryta Salkova⁷

¹Department of Neurosurgery, Dnepropetrovsk Medical Academy, Dnepropetrovsk, Ukraine

²Neurology Department of Communal Institution, Dnepropetrovsk Regional Clinical Hospital, Dnepropetrovsk, Ukraine

³Restorative Neurosurgery Department, The Institute of Neurosurgery, Kiev, Ukraine

⁴Department of Neurology with Neurosurgery, Dnepropetrovsk Medical Academy, Dnepropetrovsk, Ukraine

⁵Department of Pathological Anatomy and Forensic Medicine, Dnepropetrovsk Medical Academy, Dnepropetrovsk, Ukraine

⁶Consultative Department of Communal Institution, Dnepropetrovsk Regional Clinical Hospital, Dnepropetrovsk, Ukraine

⁷ Faculty of Medicine, Charles University in Prague, Prague, Czech Republic

Abstract

Purpose: Investigation of the mechanisms of occlusion of the vertebral arteries, radicular medullary arteries and the formation of ischemic of the brainstem.

Methods: We conducted two morphological examinations in the presence of spinal cord trauma in the cervical spine. In the first study we investigated the injured vertebral artery, and in the second study we examined the vertebral artery, spinal cord, basilar artery and brainstem. We conducted a magnetic resonance imaging examination and angiography of the cervical and vertebral arteries in a patient with a dislocation fracture of the cervical region of vertebral column. In the case with a dislocation fracture of the cervical region of vertebral column we conducted a CT and of the injured vertebral arteries, spinal cord and brainstem. A morphological examination indicated the presence of an injury of the vertebral artery wall at the site of the dislocation fracture and arterial thrombosis.

Results: The patient with the dislocation fracture of C6-C7 one vertebral artery was injured, with no evidence of total occlusion. Morphological examination indicated the presence of an injury of the vertebral artery wall at the site of the dislocation fracture and arterial thrombosis.

While investigating the vertebral arteries of the patient with the dislocation fracture of C5-C6, we revealed an endothelial injury and a thrombus formation in the vertebral, radicular and medullary arteries. In the basilar artery a thromboembolic was revealed. While investigating the brainstem, we revealed ischemia and edema of various degrees of severity.

Conclusion: Thrombosis and occlusion occurs in the arteries in the setting of the trauma of vertebral arteries in consequence of a dislocation fracture. Thrombosis and thromboembolism can impair the condition of patients and to cause ischemia in the brainstem.

Keywords: Spinal injury; Spinal circulation; Morphological examination

Introduction

According to a review of the available literature there is no information about the mechanism of occlusion of the vertebral artery and its branches, and its influence on the development of brainstem ischemia.

We conducted morphological examinations of the vertebral artery and its radicular and medullary branches, basilar artery and brain stem, which explain the mechanism of development of secondary spinal cord injuries and ischemic changes in the brainstem. It is our opinion that the primary endothelial injury of the vertebral artery, Lazorthes artery or anterior spinal artery is one of the leading mechanisms of formation of the vascular catastrophe, i.e. edema and ischemia of the brainstem and development of secondary spinal stroke. According to Virchow's triad, the extended thrombus formation occurs at the site of an endothelial injury [1].

Ascending edema of the spinal cord shall be considered as the main cause of death of patients with cervical cord injury at an early stage without complications (thromboembolism of the pulmonary artery, infectious complications etc.). However, we conducted an examination of the basilar artery and brainstem, which demonstrated the presence of

thromboembolic in the basilar artery and the development of ischemia in the brainstem, which caused the death of the patients.

Materials and Investigation Methods

Two morphological examinations in the presence of spinal cord trauma in the cervical spine were conducted in the Dnepropetrovsk State Medical Academy and Municipal Institution "Dnepropetrovsk Regional Clinical Hospital named after I.I. Mechnikov." In one case we performed a standard MRI of the injured region of the vertebral column and a selective angiography of the cervical and vertebral

***Corresponding author:** Mykola Salkov, Department of Neurosurgery, Dnepropetrovsk Medical Academy, Dzerzhinsky Street 9, Dnepropetrovsk, Ukraine-49044, Tel: +380505861749, Fax: +380562314460; E-mail: salkov@ua.fm

Received September 29, 2015; **Accepted** November 19, 2015; **Published** November 29, 2015

Citation: Salkov M, Zozylia N, Tsymbaliuk V, Dzyak L, Kozlov S, et al. (2015) New Concept of the Development of Brainstem Ischemia in the Setting of Occlusions of the Vertebral Arteries and Radicular and Medullary Arteries in the Presence of the Cervical Spinal Injury. Brain Disord Ther 4:193. doi:10.4172/2168-975X.1000193

Copyright: © 2015 Salkov M, et al. This is an open-access article distributed under the terms of the Creative Commons Attribution License, which permits unrestricted use, distribution, and reproduction in any medium, provided the original author and source are credited.

arteries for the purpose of diagnostic testing of the medullary substance, compression of the spinal cord, prevalence of edema and ischemia, and vascularization of the spinal cord. In the other case only a CT examination was performed (for technical reasons). Intravital level of neurological disorders corresponded to ASIA scale A. Morphological observations showed spinal cord compression. Surgery was not performed. Microscopic studies – colouring all micro-slides with Ehrlich hematoxylin – eosin x7 was conducted.

Case 1

A 55 year old male patient was diagnosed with spinal injury, showed contusion of the spinal cord in the cervical region, dislocation fracture of C6–C7, and tetraparesis and ASIA scale A. The patient had no dysfunction of the vertebrobasilar system. Clinical neurogenic shock was noticed. On day 1 post-injury, a magnetic resonance imaging (MRI) was performed, which identified a dislocation fracture of C6–C7, and myelopathy at the level of C6–C7 (Figure 1). A complete angiography was conducted, which revealed a dissection and stretching of the right vertebral artery. The blood circulation in the left vertebral artery was maintained (Figure 2). On day 6 post-injury, the patient died. The

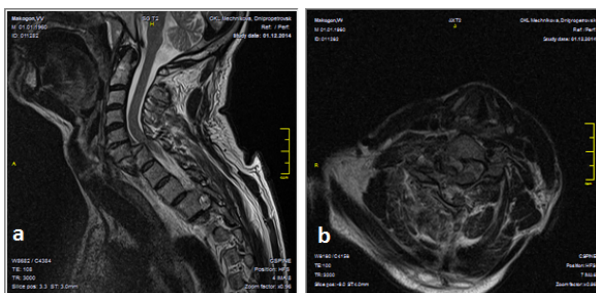


Figure 1: Magnetic resonance imaging of Case 1. A dislocation fracture of C6–C7 can be observed, along with myelopathy at the level of C6–C7. (a) Sagittal view. (b) Axial view.

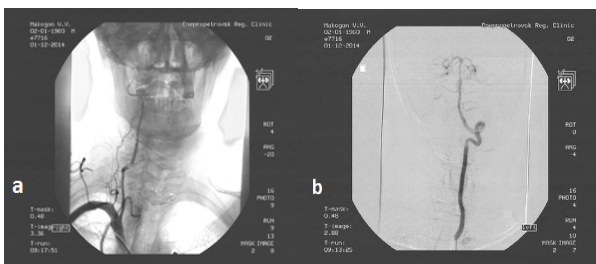


Figure 2: Angiography of the vertebral arteries. Dislocation fracture of C6–C7, posttraumatic dissection right vertebral artery. (a) Right vertebral artery. (b) Left vertebral artery.




Figure 3: Damage of the vertebral artery. The damage of the vertebral artery is marked with an arrow. Photograph of the vertebral artery.

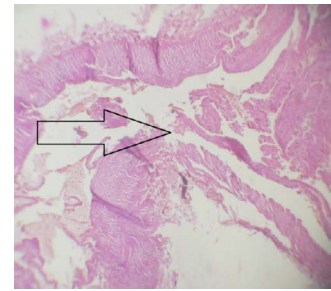


Figure 4: Detachment of the endothelium at the site of compression of the vertebral artery. The detachment of the endothelium is marked with an arrow. Photomicrograph (original magnification, x7; hematoxylin-eosin [H-E] stain).

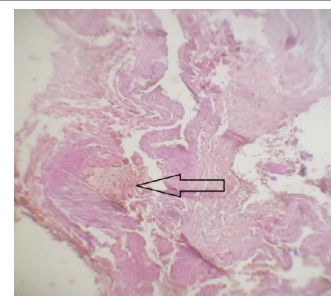


Figure 5: Section of vertebral artery showing thrombus in vertebral artery. The thrombus in vertebral artery is marked with an arrow. Photomicrograph (original magnification, x7; hematoxylin-eosin [H-E] stain).

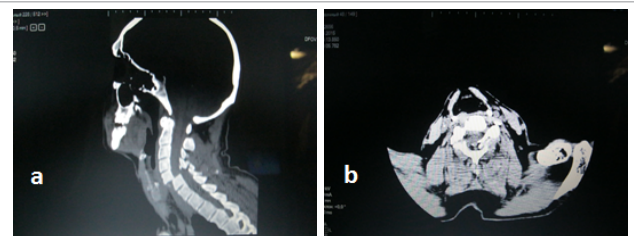


Figure 6: CT examination. Dislocation fracture of C5–C6. (a) Sagittal view. (b) Axial view.

autopsy results showed acute respiratory distress and cardiovascular insufficiency. Clinical and morphological data for the ascending edema of the spinal cord were not detected. Morphological examination of the vertebral artery revealed an endothelial injury in the area of V6 and the thrombus formation. Other vessels and the brainstem were not examined (Figures 3–5).

Case 2

A 27 year old male patient, was diagnosed with spinal injury and showed contusion of the spinal cord in the cervical region, dislocation fracture of C5–C6, and panplegia and ASIA scale A during admission. The patient displayed the clinical pattern of neurogenic shock. The patient died on the fourth day post-injury. Clinical and morphological data for the ascending edema of the spinal cord were not detected (Figure 6). The autopsy results showed acute respiratory distress and cardiovascular insufficiency. Morphological examination indicated the presence of an injury of the vertebral artery wall at the site of a dislocation fracture and arterial thrombosis (Figure 7). Thrombosis was found in the basilar artery. The intensity of the process in different areas was not the same (Figure 8). Edema and ischemia was detected in the brainstem. The intensity of the process in different areas was not

the same (Figure 9). Bleeding was also observed in the brainstem perhaps as a result of the secondary changes of ischemia (Figure 10). An earlier study made it clear that the blood circulation in the brain stem may be performed via collaterals of the ascending cervical artery, and occlusion of the vertebral artery (even bilateral) may not always have an effect on the

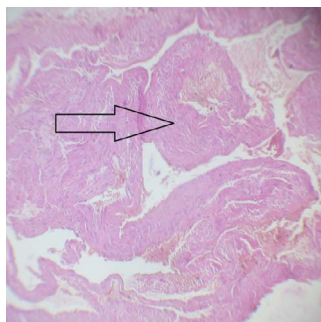


Figure 7: Thrombus in the radicular-medullary artery. Longitudinal section of the vertebral artery. Around radicular-medullary artery are thromboses in the vertebral artery. The thrombus in the radicular-medullary artery is marked with an *arrow*. Photomicrograph (original magnification, x7; hematoxylin-eosin [H-E] stain).

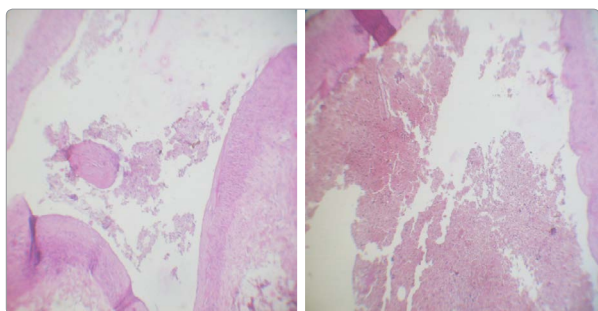


Figure 8: Thromboembolism of the basilar artery. Photomicrograph (original magnification, x7; hematoxylin-eosin [H-E] stain).

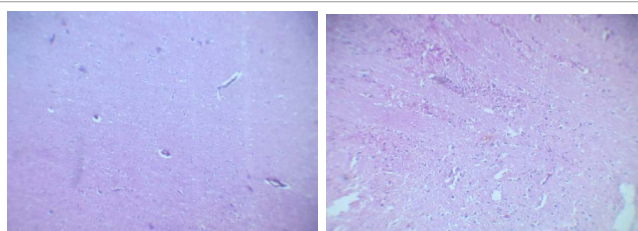


Figure 9: Edema and ischemia of the brainstem. Photomicrograph (original magnification, x7; hematoxylin-eosin [H-E] stain).

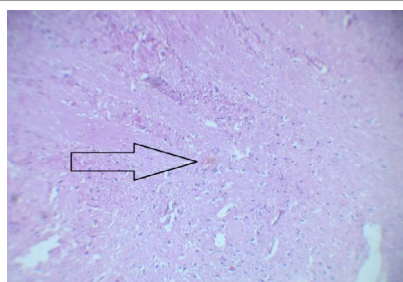


Figure 10: Single hemorrhages found in the brainstem. The hemorrhage in the brainstem is marked with an *arrow*. Photomicrograph (original magnification, x7; hematoxylin-eosin [H-E] stain).

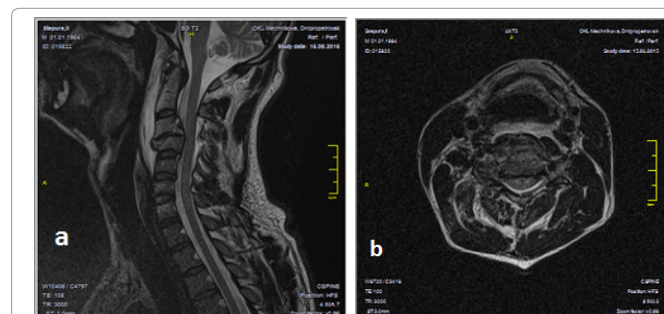


Figure 11: Magnetic resonance imaging. A dislocation fracture of C3–C4 can be observed. (a) Sagittal view. (b) Axial view.

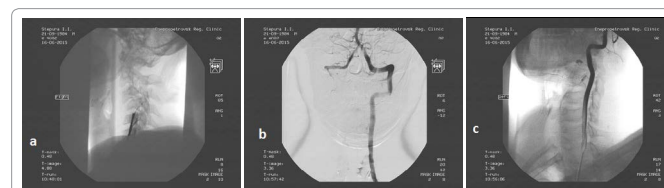


Figure 12: Angiography of the vertebral artery. Dislocation fracture of C3–C4, posttraumatic occlusion of the right vertebral artery. (a, b) System of the right vertebral artery. (c) System of the left vertebral artery.

occurrence of a stroke in the brainstem [2]. There is one more mechanism of circulatory compensation in the vertebrobasilar system (Case 3).

Case 3

A 31 year old male patient, was diagnosed with spinal injury, showed contusion of the spinal cord in the cervical region, dislocation fracture of C3–C4, without neurological disorders and ASIA scale E during admission. The patient had no dysfunction of the vertebrobasilar system. On day 2 post-injury, a magnetic resonance imaging (MRI) was performed, which identified a dislocation fracture of C3–C4 (Figure 11). On day 2, a total angiography was conducted, which revealed occlusion of the right vertebral artery. The blood circulation in the left vertebral artery was maintained. The flow of blood in the right vertebral artery was retrograde (Figure 12).

Results and Discussion

Patients suffered from spinal injuries in the cervical spine. We revealed the endothelial injury at the site of the artery injury and thrombus formation in it. According to Virchow's triad, endothelial injuries result in a thrombus formation [1]. Subsequently, many researchers described mechanisms of thrombosis and the importance of the endothelial injury for the development of a thrombus formation [3–8]. In the literature there is a description of stroke development in the brain stem, however the occurrence of a stroke is considered as a consequence of an occlusion of the vertebral artery [9–11]. The most interesting report was presented by Nakao et al., who described the clinical pattern of development of the brainstem infarction associated with the vertebral artery injury and presented a visualization by MRI and CT investigations [12]. The conducted research suggests that a thrombus formation and the thromboembolic nature of the occlusion in the artery of the cervical intumescence and development of brainstem ischemia. Thus, the theory of ascending edema of the spinal cord to the brainstem is dubious!

According to our research, the brainstem infarction may not always develop in the setting of an injury of the vertebral arteries. Additional adverse conditions are necessary. It is our opinion that the neurogenic

shock (BP<90 mm Hg) together with the severity of injury, i.e. absence of blood circulation in the artery of the cervical enlargement and anterior spinal artery, is one of the factors of development of brainstem thrombembolia. P.S. It is necessary to point out that all patients took anticlotting agents in therapeutic doses during the course of the treatment.

Conclusion

Thrombosis and occlusion occurs in the arteries in the setting of the trauma of vertebral arteries in consequence of a dislocation fracture. Thrombosis and thromboembolia can impair the condition of patients and to cause ischemia in brainstem.

References

1. Matzdorff AC, Bell WR (1998) Collected Essays on Scientific Virchow RLK Medicin. Meidinger Son & Co. Frankfurt, In. Virchow RLK. Thrombosis and emboli (1846 to 1856). Canton, Science History Publications 5 -11.110 .
2. Salkov M, Tsymbaliuk V, Dzyak L, Rodinsky A, Cherednichenko Y, et al. (2015) New concept of pathogenesis of impaired circulation in traumatic cervical spinal cord injury and its impact on disease severity: case series of four patients. *Eur Spine J* in press.
3. Asada Y, Hara S, Tsuneyoshi A, Hatakeyama K, Kisanuki A, et al. (1998) Fibrin-rich and platelet-rich thrombus formation on neointima: recombinant tissue factor pathway inhibitor prevents fibrin formation and neointimal development following repeated balloon injury of rabbit aorta. *Thromb Haemost* 80: 506-511.
4. Itoh Y, Toriumi H, Yamada S, Hoshino H, Suzuki N (2010) Resident endothelial cells surrounding damaged arterial endothelium reendothelialize the lesion. *Arterioscler Thromb Vasc Biol* 30: 1725-1732.
5. Dryjski M, Olsson P, Swedenborg J (1985) Thrombin activity appearing on the vessel wall after trauma. *Thromb Haemost* 54: 773-775.
6. Gando S, Otomo Y (2015) Local hemostasis, immunothrombosis, and systemic disseminated intravascular coagulation in trauma and traumatic shock. *Crit Care* 19: 72.
7. Gentry PA (2004) Comparative aspects of blood coagulation. Review article *Vet J* 168: 238-251.
8. Nishimura H, Naritomi H, Iwamoto Y, Tachibana H, Sugita M (1996) In vivo evaluation of antiplatelet agents in gerbil model of carotid artery thrombosis. *Stroke* 27: 1099-1103.
9. Jang D, Kim C, Lee S, Kim J (2014) Delayed Brain Infarction due to Bilateral Vertebral Artery Occlusion Which Occurred 5 Days after Cervical Trauma. *J Korean Neurosurg Soc* 56: 141-145.
10. Tokumoto K, Ueda N (2014) Cervical cord infarction associated with unilateral vertebral artery dissection due to golf swing. *Rinsho Shinkeigaku* 54: 151-157.
11. Yoshihara H, Vanderheiden TF, Harasaki Y, Beauchamp KM, Stahel PF (2011) Fatal outcome after brain stem infarction related to bilateral artery occlusion – case report of a detrimental complication of cervical spine trauma. *Patient Safe Surg* 5: 18.
12. Nakao Y, Terai H (2014) Embolic brain infarction related to posttraumatic occlusion of vertebral artery resulting from cervical spine injury: a case report. *Med Case Rep* 8: 344.

Citation: Salkov M, Zozylia N, Tsymbaliuk V, Dzyak L, Kozlov S, et al. (2015) New Concept of the Development of Brainstem Ischemia in the Setting of Occlusions of the Vertebral Arteries and Radicular and Medullary Arteries in the Presence of the Cervical Spinal Injury. *Brain Disord Ther* 4:193. doi:[10.4172/2168-975X.1000193](https://doi.org/10.4172/2168-975X.1000193)

OMICS International: Publication Benefits & Features

Unique features:

- Increased global visibility of articles through worldwide distribution and indexing
- Showcasing recent research output in a timely and updated manner
- Special issues on the current trends of scientific research

Special features:

- 700 Open Access Journals
- 50,000 editorial team
- Rapid review process
- Quality and quick editorial, review and publication processing
- Indexing at PubMed (partial), Scopus, DOAJ, EBSCO, Index Copernicus and Google Scholar etc
- Sharing Option: Social Networking Enabled
- Authors, Reviewers and Editors rewarded with online Scientific Credits
- Better discount for your subsequent articles

Submit your manuscript at: <http://www.omicsgroup.org/journals/submission/>