

## Case Report

## Successful surgical treatment of a patient with combined gunshot shrapnel injuries in the heart and brain complicated by middle cerebral artery pseudoaneurysm

Andrii Sirko<sup>a,b,\*</sup>, Ihor Kyrpa<sup>a</sup>, Vasyl Lazorishinets<sup>c</sup>, Mykola Zorin<sup>b</sup>, Yuri Cherednychenko<sup>a</sup>, Illya Plyushchev<sup>a</sup>, Dmytro Romanukha<sup>b</sup>

<sup>a</sup> Mechnikov Dnipropetrovsk Regional Clinical Hospital, Dnipro, Ukraine

<sup>b</sup> Nervous Diseases and Neurosurgery Department, Postgraduate Education Division, Dnipropetrovsk Medical Academy, The Ministry of Healthcare of Ukraine, Dnipro, Ukraine

<sup>c</sup> Amosov National Institute of Cardiovascular Surgery, Kyiv, Ukraine

## ARTICLE INFO

## Keywords:

Gunshot wound  
Craniocerebral shrapnel injury  
Shrapnel injury of the heart  
False aneurysm  
Dissectional aneurysm  
Middle cerebral artery

## SUMMARY

Successful step-by-step treatment of a combined gunshot shrapnel injury of the brain, damaging the left middle cerebral artery (MCA) branches, and penetrating myocardium injury is discussed. Open brain and heart surgeries were performed. A left MCA pseudoaneurysm was formed postoperatively. Endovascular exclusion of the left MCA pseudoaneurysm was performed using detachable micro coils. Finally, plastic reconstruction of the posttraumatic cranial vault defect was performed using a dynamic titanium plate.

Treatment of severe combined gunshot shrapnel brain injury with formation of MCA pseudoaneurysm and a penetrating myocardium injury requires a multimodal approach involving related specialists (neurosurgeon, cardiologist and interventional radiologist).

## Introduction

Cerebral vessel pseudoaneurysm due to a penetrating craniocerebral injury is a rare occurrence, accounting for ~1% of all cerebrovascular aneurysms [1,2]. The mortality rate of pseudoaneurysms is up to 50% regardless of the injury type [3].

The occurrence of intracranial pseudoaneurysm after severe penetrating craniocerebral injury varies from 20% to 50% in some populations [4–7]. The greatest experience in the treatment of cerebrovascular pseudoaneurysms due to penetrating craniocerebral injuries was obtained during military conflicts in Iran, Lebanon and Libya [4,7,8].

Aarabi [4] identified eight aneurysms of the anterior parts of the circle of Willis in 225 consecutive patients who underwent cerebral angiography for head injuries, which accounted for 3% of all cases. In 1991, Haddad [7] published 30 cases of pseudoaneurysm formations after gunshot head injuries. In the series, pseudoaneurysms after injury to the MCA and its branches were found in 13 patients. Only two cases from the series had aneurysms in the posterior parts of the circle of Willis (one patient had basilar artery injuries; the other, superior cerebellar artery injuries).

Surgical treatment of pseudoaneurysms is the optimal policy [9], including clipping [6], removal [7] and trapping [9]. Advances in endovascular technology have provided an alternative to open surgical interventions in such pathologies. The most common

\* Corresponding author at: Cerebral Neurosurgery Department No. 2, Mechnikov Dnipropetrovsk Regional Clinical Hospital, 14 Soborna Square, Dnipro 49005, Ukraine.

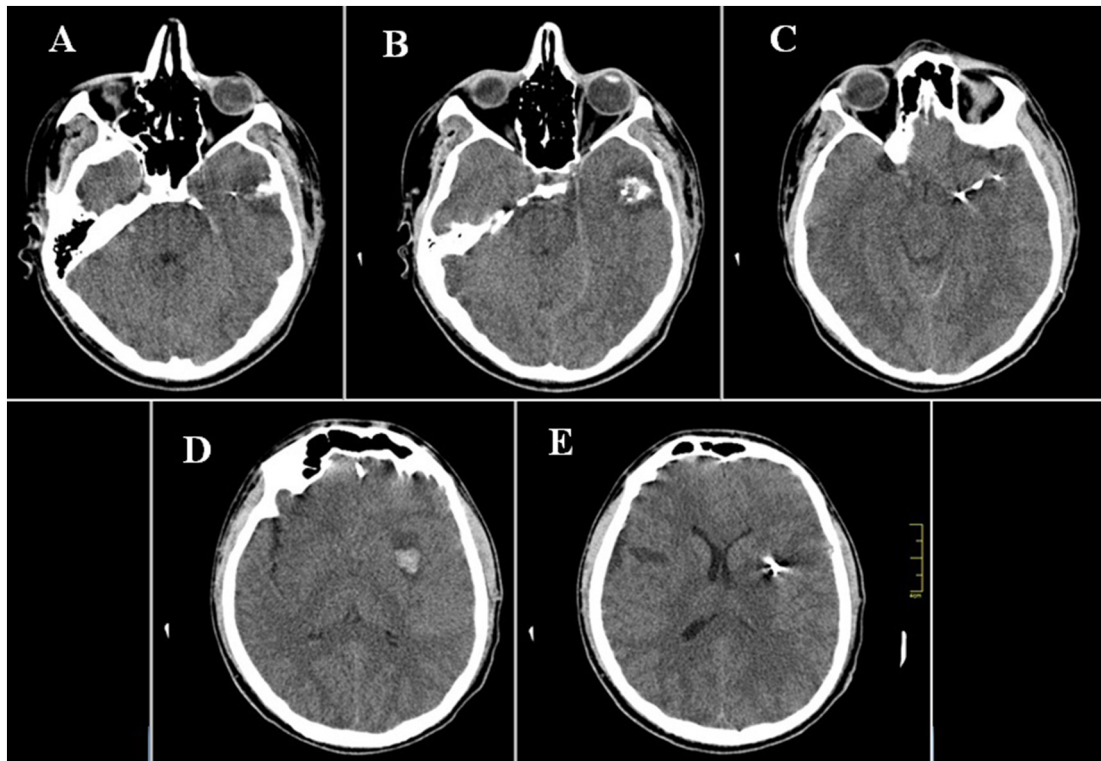
E-mail address: [sirkoscience@gmail.com](mailto:sirkoscience@gmail.com) (A. Sirko).

<https://doi.org/10.1016/j.tcr.2018.11.001>

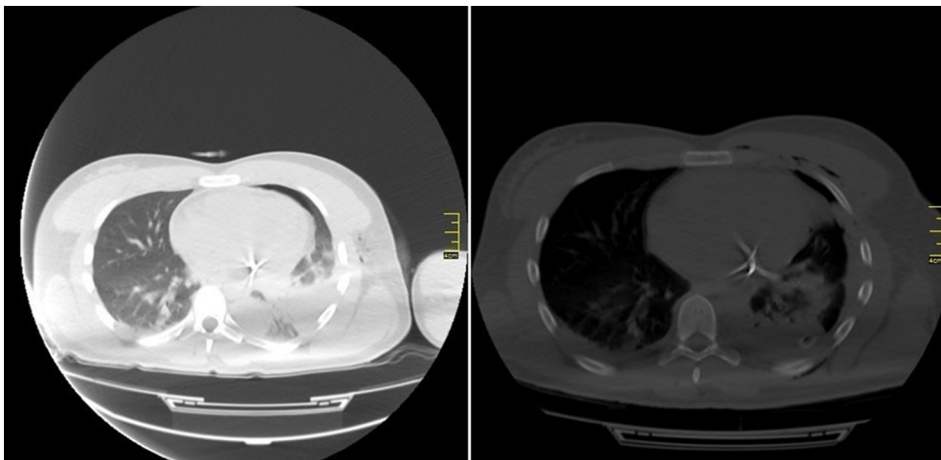
Accepted 12 November 2018

Available online 24 November 2018

2352-6440/ © 2018 The Authors. Published by Elsevier Ltd. This is an open access article under the CC BY-NC-ND license (<http://creativecommons.org/licenses/by-nc-nd/4.0/>).



**Fig. 1.** Post-injury brain SCT. A–Entry wound in the squamous part of the left temporal bone; B–proximal (in relation to entry wound) focus of contusion and crush injury of the left temporal lobe with bone fragments, massive subarachnoid haemorrhage in the parasellar cisterns; C–two foreign bodies of metallic density (projectile fragments) and bone fragment in the left temporal lobe; D–distal contusion focus in the basal nuclei, left side; E–third fragment in the left temporal lobe.

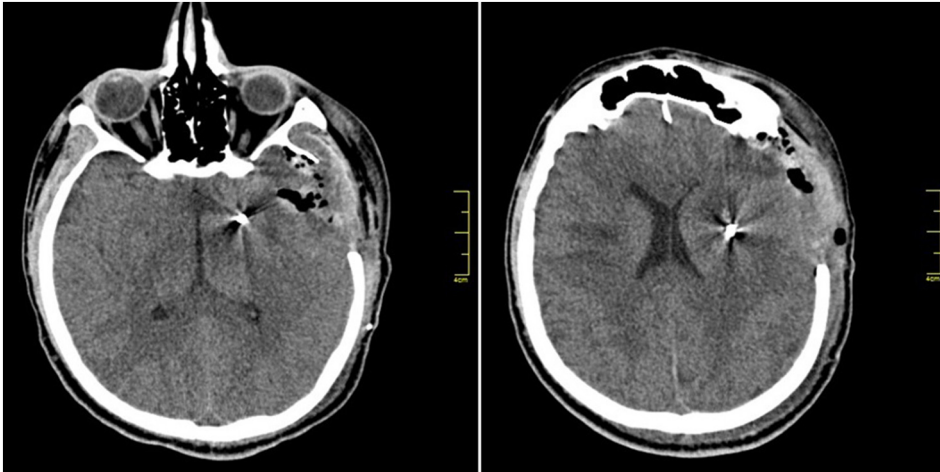


**Fig. 2.** Post-injury SCT of the thoracic organs. Demonstration of penetrating heart injury with a foreign body in the myocardium, left lung contusion and left haemopneumothorax.

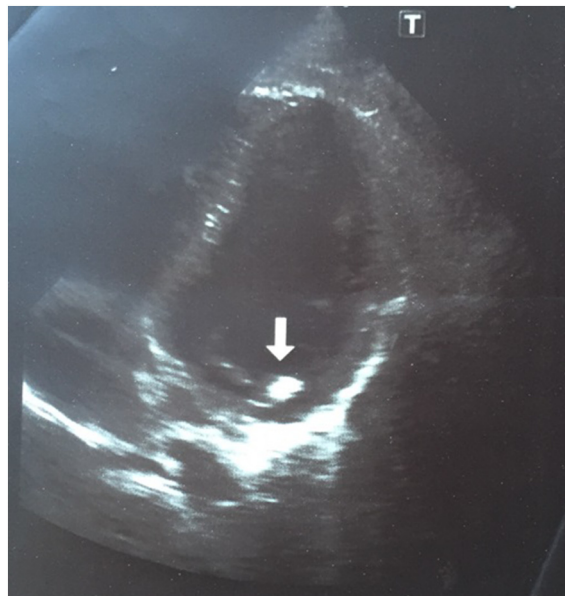
endovascular methods include embolisation with coils, glue embolisation [10] or stenting [11].

Gunshot heart injuries often result in death. Ivatury reported a mortality rate of approximately 71% following penetrating heart injuries in patients with unstable vital functions [12]. Additional diagnostic methods, such as echocardiography and spiral computed tomography (SCT), help the physicians make the right clinical decisions for patients with stable vital functions [13,14]. Similarly, patients with unstable vital functions shall undergo emergency surgery, which ensures lower mortality in this category of patients [12,15].

Late complications of gunshot heart injuries include bleeding, perforation (cardiac tamponade), thrombosis, rhythm disturbances



**Fig. 3.** Day 1 postoperative brain SCT. Removed left temporal lobe contusion foci, bone fragments and accessible fragment. Visualisation of the brain substance prolapse to craniotomy bone defect and two non-removed fragments at the end of injury canal.



**Fig. 4.** Follow-up EchoCG. A fragment of projectile in the depth of the left ventricle wall (basal areas under the base of posterior mitral leaflet).

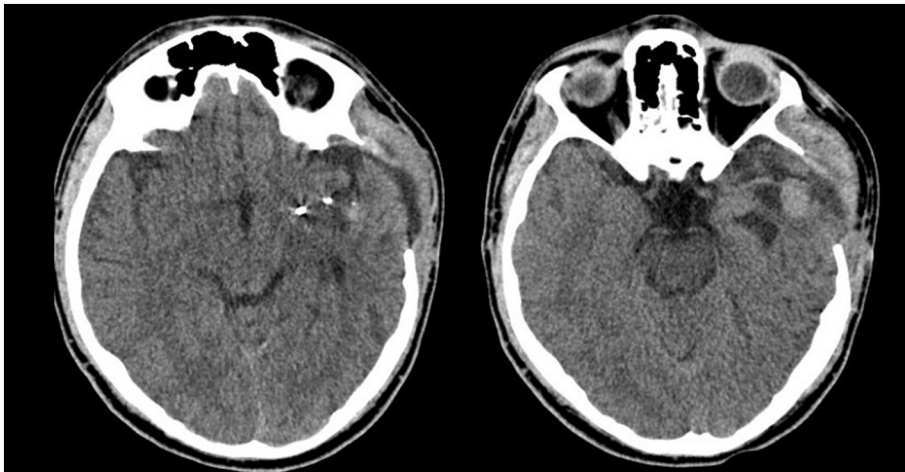
and infections. Such complications are usually associated with size and location of the injuring projectile [16].

To the best of our knowledge, we present the first case of successful treatment of a patient with shrapnel brain injury with MCA pseudoaneurysm and shrapnel myocardium injury.

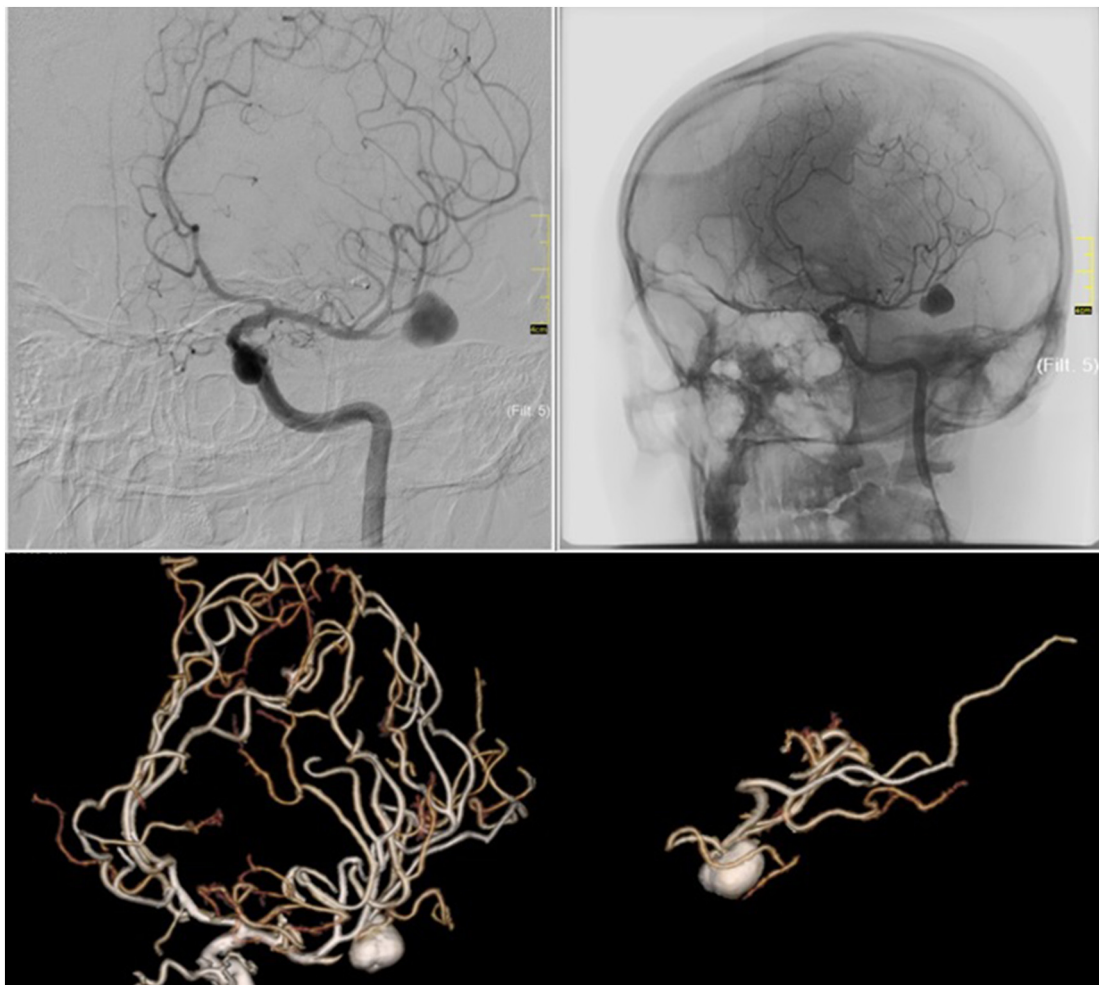
### Case presentation

The patient sustained a shrapnel injury in a local armed conflict in Eastern Ukraine as a result of mortaring 120-mm mines. First aid was provided in a military field hospital. The patient's condition was severe at admission, with a Glasgow Coma Scale score of 11. The pupils were equal and reactive to light. The patient was breathing spontaneously, with a respiratory rate of 19 cycles/min. Vesicular breathing was heard in the upper lung field, which was attenuated at the left lung apex. Heart sounds were rhythmical and muffled. The patient had a blood pressure of 80/60 mm Hg, and heart rate of 96 bpm. A round-shaped injury, with approximately 1-cm diameter, with irregular edges in the left temporal region and moderate bleeding, was found. Multiple irregular-shaped injuries, with 0.5- to 2-cm diameter, were found on the left anterolateral chest surface.

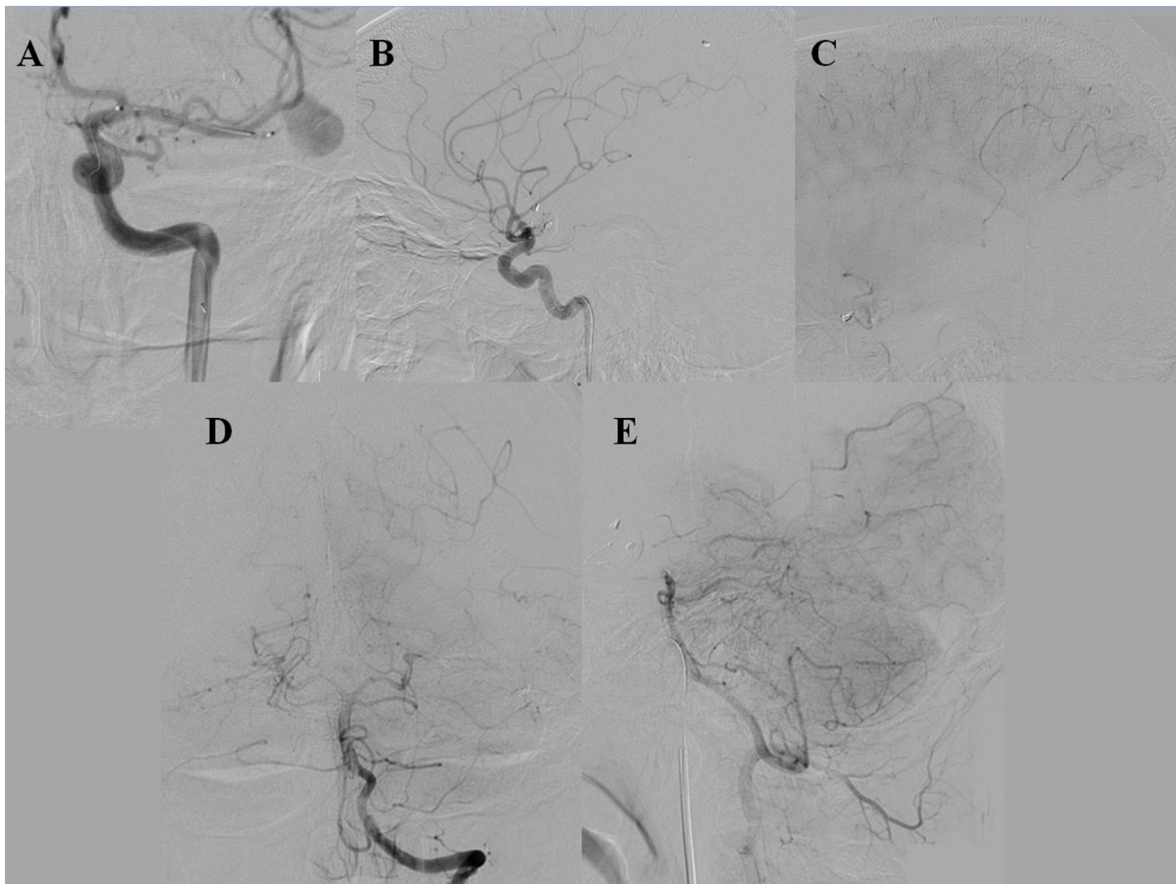
Aseptic bandages were applied, and vital functions were stabilised. The patient was transferred to a regional clinical hospital by helicopter. Brain SCT showed a penetrating, non-perforating skull and brain injury, with entrance hole in the squamous part of the left temporal bone. Areas of increased density of brain parenchyma were seen in the temporal lobe, along the injury canal,



**Fig. 5.** Three-month post-injury brain SCT. Visualisation of two non-removed fragments and hyperdense focus in the left temporal lobe—pseudoaneurysm (dissectional) of the left MCA branches.



**Fig. 6.** Cerebral angiography. Dissectional aneurysm of the M2 segment of the left MCA, with three MCA branches outgoing from the aneurysm to the temporal lobe, gross stenosis of M2 segment before the aneurysm.



**Fig. 7.** A–Carotid angiography, left side, semi-lateral projection (intraoperative): a microcatheter inserted into the M2 branch of the left MCA. B–The M2 branch is embolised with microcoils; aneurysm and outgoing M2 branches are not visualised (avascular zone in the MCA territory), M2 branch supplying blood to superior segments of the left temporal lobe is preserved; C–clearly seen cortical collaterals from parietal MCA branches; D, E–clearly seen cortical collaterals from vertebrobasilar system vessels.

represented by brain contusion and crush injury foci with haemorrhages (Fig. 1).

Chest SCT showed reduced volume of the left lung. Wedge-shaped thickening of the parenchyma of the superior lobe of the left lung, with a wide base facing pericostal pleura, could be seen (Fig. 2).

The patient had a penetrating multifragmental craniocerebral injury with three foreign bodies of metallic density and small bone fragments in temporal lobe parenchyma (left side), and focal temporal lobe contusions and intracerebral haematomas (left side). Penetrating heart injury with a foreign body in the myocardium, left lung contusion and left-sided haemopneumothorax were found.

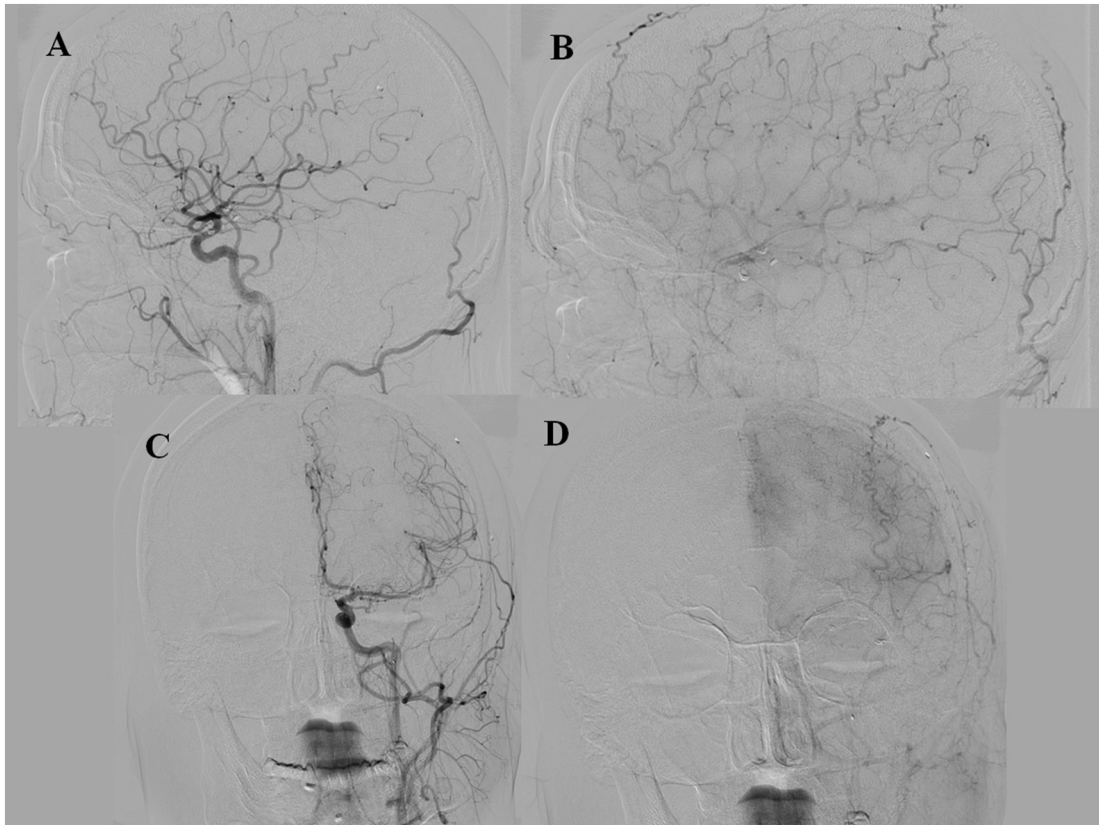
Left thoracotomy was initially performed after the SCT and diagnosis. Left ventricle injury was sutured. The superior lobe of the left lung was subjected to atypical resection. The pleural cavity was drained. During the surgery, a penetrating injury was detected on the posterolateral wall of the left ventricle, with a 5 × 5-mm hole. The hole was sewn with a U-shaped seam on a Teflon gasket. The latter was resected instrumentally considering the perforated injury canal with a haematoma in the V lung segment. No metal fragment was found in the pericardium or pleural cavity during the surgery.

Surgical treatment of penetrating gunshot craniocerebral injury was performed after vital function stabilisation. Intracerebral left temporal lobe haematoma, one metal fragment and small bone fragments were removed. Damage to the MCA branches and intensive bleeding from the left MCA branches were detected. Temporary MCA clipping and haemostasis were performed using bipolar coagulation and Surgicel. No bleeding was noted after temporary clip removal. The left temporal and frontal bones (less than 9 × 10 cm) were resected, and duraplasty was performed using autogenous tissues.

The following day after the surgery, the follow-up brain SCT showed brain matter prolapse to the craniotomy bone defect, air along the injury channel and two foreign bodies of metallic density at the end of the injury channel (Fig. 3).

A follow-up echocardiography showed a foreign body (projectile fragment) penetrating into the depth of the left ventricle wall (basal areas under the base of posterior mitral leaflet) without traumatic damage to mitral leaflet structures. Myocardial contractility was preserved (Fig. 4). A follow-up electrocardiography showed subendocardial hypoxia and microfocal myocardial changes.

Due to the changes revealed by electrocardiogram and echocardiography, the patient was transported to Amosov National Institute of Cardiovascular Surgery, Kyiv, Ukraine, for further treatment.



**Fig. 8.** Three-month post-embolisation follow-up cerebral angiography. Retrograde blood flow through cortical collaterals along all MCA branches, except for embolised M2 with the false aneurysm.

The patient underwent surgery to remove the foreign body from the left ventricle's myocardium. Sternotomy was performed during the surgery, and the pericardium was opened. A CPB pump was connected. Right and partial left atriotomies were performed. A metal fragment was found and removed from under the posterior wall of the left ventricle. The left ventricle cavity was revised. Air embolism was prevented, and the cardiac chambers were sealed. Subsequently, heart function was restored. Haemostasis was performed. The pericardium and anterior mediastinum were drained. No complications were detected in the postoperative period. The patient was transported to a military hospital for further rehabilitation after 8 days.

A follow-up brain SCT was performed 3 months after the injury. In a non-contrast study, a  $1.5 \times 1$ -cm hyperdense focus was found in the left temporal lobe in the burr hole. Given the shape, location and connection with the MCA, a pseudoaneurysm of the M2 segment of the left MCA was suspected (Fig. 5).

Selective cerebral angiography confirmed dissection aneurysm of the M2 segment of the left MCA, with three MCA branches outgoing from the aneurysm to the temporal lobe, gross stenosis of M2 segment before the aneurysm (Fig. 6).

The patient underwent X-ray endovascular deconstructive exclusion of dissected M2 aneurysm (temporal branch of the left MCA) with detachable microcoils. During temporary M2 segment occlusion, the MCA branches supplying the left temporal lobe were retrogradely contrasted from the vertebral artery through cortical collaterals. The MCA branch supplying the superior sections of the left temporal lobe was retrogradely contrasted from the left internal carotid artery through collaterals from the parietal MCA branches. The patient underwent MoCA with a 4-min interval. The results were not worse than those during the preoperative tests. Endovascular stationary aneurysm occlusion was performed with aneurysm-bearing M2 branch of the left MCA. Detachable microcoils, GDC Ultrasoft  $2 \text{ mm} \times 6 \text{ cm}$  and MicroPlex Helical-Soft  $2 \text{ mm} \times 68 \text{ cm}$ , were placed in this branch. In follow-up angiographic studies, the aneurysm was not contrasted; the arteries contrasting the left temporal lobe were retrogradely contrasted through cortical collaterals from the vertebrobasilar system and parietal left MCA branches. Postoperative follow-up MoCA showed that the outcome did not deteriorate (Fig. 7).

No data were found confirming the functioning saccular aneurysm during follow-up selective cerebral angiography 3 months after X-ray endovascular occlusion. Blood flow to all MCA branches was restored retrogradely through available cortical collaterals, except for embolised M2 with the aneurysm (Fig. 8). After follow-up angiography, plastic surgery was performed for extensive defect of left temporal and frontal bones by using a custom titanium plate based on stereolithographic 3D model. The patient was discharged postoperatively for further out-patient treatment under the neuropathologist's supervision.

## Discussion

A metal fragment in myocardium was not detected during primary immediate intervention for haemopneumothorax. Repeated planned, CPB pump-assisted surgery in a specialised cardiac surgical centre was performed to remove the fragment.

Metal fragments in the brain were not removed given their small size and depth. Locating them at the bottom of the injury canal could cause additional injury to the brain substance. One of the three fragments, freely placed along the injury canal, was removed. Subsequent follow-up showed no inflammatory changes in the brain or convulsive seizures. Additional cranial vault bone resection with dura mater opening and subsequent duraplasty was required for external decompression, given the presence of intraoperative enema of brain substance.

Parietal MCA injury subsequently caused dissectional MCA aneurysm. Reconstructive aneurysm exclusion with the MCA permeability preservation was associated with greater risks of complications, given that the aneurysm was inherently dissectional with three branches. Exclusion of this dissectional aneurysm represented technical difficulties for both open and endovascular interventions.

Occlusion test with microcoils was initially performed, with the assessment of neurological status and collateral blood supply from the vertebrobasilar system by simultaneous catheterisation of two vascular systems. Subject to well-developed collaterals and absence of occlusion test deficiency, the surgery was planned to be completed with stationary occlusion. In case of increased neurological deficit, stopping the occlusion and creating a high-flow anastomosis between the external carotid artery and a large branch from the aneurysmal sac were planned. After the creation of anastomosis, overlapping the supporting branch was planned.

## Conclusion

Treatment of severe combined gunshot shrapnel brain injury with formation of MCA pseudoaneurysm and a penetrating heart injury requires multimodal approach involving related specialists (neurosurgeon, cardiothoracic surgeon and interventional radiologist). Active surgical tactics in such complex combined injury proved to be effective and was associated with a satisfactory outcome.

## References

- [1] J.H. Han, E.J. Koh, H.Y. Choi, J.S. Park, J.M. Lee, Visualization of a traumatic pseudoaneurysm at internal carotid artery bifurcation due to blunt head injury: a case report, *Korean J. Neurotrauma* 10 (2014) 126–129.
- [2] K.S. Bhaisora, S. Behari, C. Godbole, R.V. Phadke, Traumatic aneurysms of the intracranial and cervical vessels: a review, *Neurol. India* 64 (2016) 14–23.
- [3] R.M. Crowell, C.S. Ogilvy, Traumatic intracranial aneurysms, *Surgical Management of Neurovascular Disease*, Williams & Wilkins, Baltimore, 1995, pp. 377–384.
- [4] B. Aarabi, Traumatic aneurysms of brain due to high velocity missile head wounds, *Neurosurgery* 22 (1988) 1056–63.
- [5] A. Amirjamshidi, H. Rahmat, K. Abbassioun, Traumatic aneurysms and arteriovenous fistulas of intracranial vessels associated with penetrating head injuries occurring during war: principles and pitfalls in diagnosis and management: a survey of 31 cases and review of the literature, *J. Neurosurg.* 84 (1996) 769–780.
- [6] R.S. Bell, A.H. Vo, R. Roberts, J. Wanebo, R.A. Armonda, Wartime traumatic aneurysms: acute presentation, diagnosis, and multimodal treatment of 64 craniocervical arterial injuries, *Neurosurgery* 66 (2010) 66–79.
- [7] F.S. Haddad, G.F. Haddad, J. Taha, Traumatic intracranial aneurysms caused by missiles: their presentation and management, *Neurosurgery* 28 (1991) 1–7.
- [8] T. Hakan, A.C. Kaur, Traumatic pseudoaneurysms of the head in war time: report of two unusual cases, *Turk. Neurosurg.* (2017) 1–6.
- [9] P.S. Larson, A. Reisner, D.J. Morassutti, B. Abdulhadi, J.E. Harpring, Traumatic intracranial aneurysms, *Neurosurg. Focus* 8 (2000) 1–6.
- [10] C.M. Bonfield, R. Grandhi, B.T. Jankowitz, E.C. Tyler-Kabara, Traumatic intracranial aneurysm after penetrating brain trauma, *BMJ Case Rep.* 2014 (2014) bcr2014206130, <https://doi.org/10.1136/bcr-2014-206130>.
- [11] U.K. Bodanapally, N. Saksobhavit, K. Shanmuganathan, B. Aarabi, A.K. Roy, Arterial injuries after penetrating brain injury in civilians: risk factors on admission head computed tomography, *J. Neurosurg.* 122 (2015) 219–226.
- [12] R.R. Ivatury, M. Rohman, F.M. Steichen, Y. Gunduz, M. Nallathambi, W.M. Stahl, Penetrating cardiac injuries: twenty-year experience, *Am. Surg.* 53 (1987) 310–317.
- [13] F.A. Siddiqui, J. Kabeer, S. Shahabuddin, Surviving shot through the heart: management in two cases, *J. Pak. Med. Assoc.* 65 (2015) 93–94.
- [14] S.A. Bellister, B.M. Dennis, O.D. Guillaumondegui, Blunt and penetrating cardiac trauma, *Surg. Clin. North Am.* 97 (2017) 1065–1076.
- [15] J. Vodička, V. Špidlen, V. Třeška, Š. Vejvodová, J. Doležal, A. Židková, et al., [Penetrating chest trauma—experience of the Pilsen University Hospital Trauma Centre], *Rozhl. Chir.* 96 (2017) 463–468.
- [16] P.N. Symbas, A.L. Picone, C.R. Hatcher, S.E. Vlasiv-Hale, Cardiac missiles. A review of the literature and personal experience, *Ann. Surg.* 211 (1990) 639–648.