

МЕДИЧНІ ПЕРСПЕКТИВИ

MEDIČNI PERSPEKTIVI

2024 Том XXIX № 1

Науковий журнал
Дніпровського державного медичного університету

Виходить 4 рази на рік

Заснований у 1996 році

Адреса редакції

Редакція журналу
«Медичні перспективи»
Дніпровський державний
медичний університет
вул. Володимира Вернадського, 9
м. Дніпро, 49044, Україна

Телефон
+38(050)629-55-58

e-mail:
medpers@dmu.edu.ua
<https://medpers.dmu.edu.ua>

Засновник
Дніпровський державний медичний університет

Ідентифікатор ДДМУ
в Реєстрі суб'єктів у сфері медіа R30-00972

Свідоцтво про внесення суб'єкта видавничої
справи до державного реєстру видавців
ДК №7350 від 07.06.2021 р.

Періодичність – 4 рази на рік

Видається згідно з постановою вченої ради
Дніпровського державного
медичного університету
(протокол № 8 від 28.03.2024 р.)

Відповідно до Порядку формування
Переліку наукових фахових видань України,
журналу "Медичні перспективи"
присвоєна категорія "А"
(наказ МОН України № 1188 від 24.09.2020 р.)

Перелік спеціальностей:
222, 221, 225, 226, 227, 228, 229
(наказ МОН України від 15.04.2021 № 420)

Журнал зареєстровано в міжнародних
наукометричних базах та каталогах:
Scopus, ESCI (Web of Science), Crossref,
Ulrich's Periodicals Directory, ProQuest,
EBSCO, DOAJ, MyScienceWork,
ERIH PLUS OCLC WorldCat, MJL,
Dimensions, OpenDOAR, EZB, NLM,
OpenAIRE, Zenodo, BASE, Google Scholar

Підписано до друку 01.04.2024 р.
Формат 60x84/8. Друк офсетний
Папір офсетний. Умовн. друк. арк. 13,9
Зам. № 15. Тираж 500 примірників

РЕДАКЦІЙНА КОЛЕГІЯ

Головний редактор

Т.О. ПЕРЦЕВА

Науковий редактор

В.Й. МАМЧУР

Відповідальний редактор

О.Б. НЕХАНЕВИЧ

Куратори розділів

Теоретична медицина – І.С. Шпонька,
Е.М. Білецька, О.Г. Родинський, О.А. Подплетня
Клінічна медицина – Л.В. Усенко, О.Є. Лоскутов,
В.А. Потабашній, О.О. Гудар'ян, І.Л. Височина,
О.В. Курята, В.О. Потапов, Я.С. Березницький,
В.В. Огоренко
Профілактична та соціальна медицина –
В.М. Лехан, О.А. Шевченко

Склад редакційної ради

К.М. Амосова (Київ), І.М. Бондаренко (Дніпро),
Л.А. Дзяк (Дніпро), З.М. Дубоссарська (Дніпро),
В.М. Коваленко (Київ), Г.М. Кременчуцький
(Дніпро), П. Радд (Великобританія), А.М. Сердюк
(Київ), Ю.М. Степанов (Дніпро), В.П. Стусь
(Дніпро), Ю.І. Фещенко (Київ), І.М. Хоменко
(Київ), Л.Р. Шостакович-Корецька (Дніпро),
Ш. Селл (Німеччина), В. Зіберт (Німеччина),
О. Злотник (Ізраїль), Л. Ростейнг (Франція),
Д.Д. Іванов (Київ), І.М. Григус (Рівне), А. Айдетіс
(Литва), М. Грабовський (Польща), Т.В. Колесник
(Дніпро), Л.І. Конопкіна (Дніпро), О. Брюер
(Бельгія), К.Ю. Гашинова (Дніпро), М. Льор
(Швеція), В. Недзвецький (Туреччина),
К. Ягер (Нідерланди), Д.О. Степанський (Дніпро),
О.П. Крупський (Дніпро), Т.В. Святенко (Дніпро),
Дж. Джордж (Великобританія), Р.Е. Стівенс
(США), А.А. Інджикулян (США), Н. Веронезе
(Італія)

Літературні редактори

М.Ю. Сидора,
І.М. Клименко

Дизайн та оригінал-макет

Л.М. Григорчук

Відповідальний секретар

К.В. Соколова

Макетування та друкування

виконано ВТК "Редактор" та "Друкар" ДДМУ

on experimental glomerulonephritis. *Front Mol Biosci.* 2023;10:1223972.

doi: <https://doi.org/10.3389/fmolb.2023.1223972>

18. Ying J, Zhang C, Wang Y, et al. Sulodexide improves vascular permeability via glycocalyx remodelling in endothelial cells during sepsis. *Front Immunol.* 2023;14:1172892.

doi: <https://doi.org/10.3389/fimmu.2023.1172892>

19. Miguez PA, Bash E, Musskopf ML, et al. Control of tissue homeostasis by the extracellular matrix: Synthetic heparan sulfate as a promising therapeutic for periodontal health and bone regeneration. *Periodontol 2000.* 2023;00:1-22. doi: <https://doi.org/10.1111/prd.12515>

20. Klisic A, Patoulias D. The Role of Endocan in Cardiometabolic Disorders. *Metabolites.* 2023;13(5):640. doi: <https://doi.org/10.3390/metabo13050640>

21. Sullivan RC, Rockstrom MD, Schmidt EP, Hippensteel JA. Endothelial glycocalyx degradation during sepsis: Causes and consequences. *Matrix Biol Plus.* 2021;12:100094.

doi: <https://doi.org/10.1016/j.mbplus.2021.100094>

22. Diaz-Salmeron R, Cailleau C, Denis S, Pouchel G, Bouchemal K. Hyaluronan nanoplatelets exert an intrinsic anti-inflammatory activity in a rat model of bladder painful syndrome/interstitial cystitis. *J Control Release.* 2023;356:434-47.

doi: <https://doi.org/10.1016/j.jconrel.2023.03.014>

23. Wang X, Liu D, Li D, et al. Combined treatment with glucosamine and chondroitin sulfate improves rheumatoid arthritis in rats by regulating the gut microbiota. *Nutr Metab (Lond).* 2023;20(1):22. doi: <https://doi.org/10.1186/s12986-023-00735-2>

24. Zhang Y, Wang ZL, Deng ZP, Wang ZL, Song F, Zhu LL. An extracellular matrix-inspired self-healing composite hydrogel for enhanced platelet-rich plasma-mediated chronic diabetic wound treatment. *Carbohydr Polym.* 2023;315:120973.

doi: <https://doi.org/10.1016/j.carbpol.2023.120973>

25. Matsyska YK, Akimov OY, Mykytenko AO. Influence of corvutin and metformin on biochemical changes in lacrimal glands of rats during water avoidance stress modeling. *Oftalmologicheskii Zhurnal.* 2022;97(3):39-44. doi: <https://doi.org/10.31288/oftalmolzh202233944>

26. Skrypnyk I, Maslova G, Lymanets T, Gushchenko I. L-arginine is an effective medication for prevention of endothelial dysfunction, a predictor of anthracycline cardiotoxicity in patients with acute leukemia. *Exp Oncol.* 2017;39(4):308-11.

doi: [https://doi.org/10.31768/2312-8852.2017.39\(4\):308-311](https://doi.org/10.31768/2312-8852.2017.39(4):308-311)

27. Chekalina NI, Kazakov YM, Mamontova TV, Vesnina LE, Kaidashev IP. Resveratrol more effectively than quercetin reduces endothelium degeneration and level of necrosis factor α in patients with coronary artery disease. *Wiad Lek.* 2016;69(3 pt 2):475-9.

Стаття надійшла до редакції 02.10.2023;
затверджена до публікації 19.02.2024




UDC 616.831-001.1-091.8-092.9

<https://doi.org/10.26641/2307-0404.2024.1.300497>

S.V. Kozlov*, 

Yu.V. Kozlova, 

N.S. Bondarenko, 

O.O. Bondarenko 

HISTOPATHOLOGICAL AND ULTRASTRUCTURAL CHANGES IN THE RATS BRAIN AFTER AIR SHOCK WAVE IMPACT

Dnipro State Medical University

Volodymyra Vernadskoho str., 9, Dnipro, 49044, Ukraine

Дніпровський державний медичний університет

вул. Володимира Вернадського, 9, Дніпро, 49044, Україна

**e-mail: tanatholog@i.ua*

Цитування: *Медичні перспективи.* 2024. Т. 29, № 1. С. 16-26

Cited: *Medicni perspektivi.* 2024;29(1):16-26

Key words: *cerebral cortex, hippocampus, blast-induced brain injury, rats, histopathology, ultrastructure, digital morphometry, ImageJ*

Ключові слова: *кора головного мозку, гіпокамп, вибухо-індукована травма мозку, щури, гістопатологія, ультраструктура, цифрова морфометрія, ImageJ*

Abstract. Histopathological and ultrastructural changes in the rats brain after air shock wave impact. Kozlov S.V., Kozlova Yu.V., Bondarenko N.S., Bondarenko O.O. *The using of explosive substances and devices can lead to brain injuries, the diagnosis of which requires the determination of primary biomarkers. Therefore, the aim was to establish and study histopathological and ultrastructural changes in the rats brain after exposure to an air blast wave. The study was carried out on 18 male Wistar rats, which were randomly divided into two groups: sham (n=9) and experimental (n=9). The animals of the experimental group were anesthetized with halothane and gently fixed in a horizontal position on the abdomen with the front part of the rat's muzzle at a distance of 5 cm from the device opening and subjected to an excess pressure of 26-36 kPa. Animals of both groups were decapitated, brains were removed, fixed, histopathological and ultrastructural analyzes were conducted using standard methods. Intergroup differences were assessed by Mann-Whitney U-test. Light microscopy revealed primary lesions in the form of small focal, multifocal hemorrhages, cerebral vessel ruptures and microscopic ruptures of the brain substance. In almost all brain samples, there is a significant saturation of the venous vessels with the presence of erythrocyte stasis. Violation of the blood-brain barrier, the presence of edema of the perivascular space, and petechial hemorrhages in the neuropil were registered ultrastructurally. Based on the study results, a morphological algorithm for assessing primary histostructural intracranial brain injuries and their consequences after exposure to an air shock wave was proposed. The injuries were found to be caused by the direct traumatic effect of the air shock wave. In the acute post-traumatic period, histopathological and ultrastructural changes in the brain can manifest as changes in neurons and in the blood-brain barrier and be accompanied by perivascular multifocal small-focal hemorrhages, neuropil ruptures, edema of pericellular and perivascular spaces, which together can be considered as biomarkers of primary traumatic changes after exposure to an air shock wave.*

Реферат. Гістопатологічні та ультраструктурні зміни в головному мозку щурів після впливу повітряної вибухової хвилі. Козлов С.В., Козлова Ю.В., Бондаренко Н.С., Бондаренко О.О. *Використання вибухових речовин і пристроїв може призводити до травм головного мозку, діагностика яких вимагає визначення первинних специфічних біомаркерів. Тож метою роботи стало встановлення і вивчення гістопатологічних та ультраструктурних змін у головному мозку щурів після впливу повітряної вибухової хвилі. Дослідження було проведено на 18 самцях щурів Вістар, які були рандомним чином розподілені на дві групи: контрольну (n=9) та експериментальну (n=9). Тварин експериментальної групи анестезували галотаном і щільно фіксували в горизонтальному положенні на животі передньою частиною морди щура на відстані 5 см від отвору пристрою та надавали впливу надлишкового тиску 26-36 кПа. Тварин обох груп декапітували, видаляли головний мозок, фіксували та проводили гістопатологічний і ультраструктурний аналізи стандартними методами. Міжгрупові відмінності оцінювали за U-критерієм Манна-Вітні. Під час світлової мікроскопії встановлені первинні ураження у вигляді дрібних вогнищевих, мультифокальних крововиливів, розривів церебральних судин і мікроскопічних розривів речовини головного мозку. Майже у всіх взірцях головного мозку спостерігалось значне насичення судин венозної ланки з наявністю стази еритроцитів. Ультраструктурно реєстрували порушення гематоенцефалічного бар'єру, наявність набряку периваскулярного простору, петехіальних крововиливів у нейрополі. За результатами дослідження запропоновано морфологічний алгоритм оцінки первинних гістоструктурних внутрішньочерепних ушкоджень головного мозку та їх наслідків після впливу повітряної ударної хвилі. Виявлені ушкодження утворилися внаслідок прямої травматичної дії повітряної ударної хвилі. У гострому посттравматичному періоді гістопатологічні та ультраструктурні зміни головного мозку можуть проявлятися у вигляді змін як з боку нейронів, так і з боку гематоенцефалічного бар'єру та супроводжуватися навколосудинними мультифокальними дрібновогнищевими крововиливами, розривами нейрополя, набряком перицелюлярного та периваскулярного просторів, які в сукупності можна розглядати в якості біомаркерів первинних травматичних змін після впливу повітряної ударної хвилі.*

The pathogenesis of brain disorders is of extreme relevance for military and civilians exposed to blast factors, in particular blast waves. The utilization of explosives and devices in military conflicts has a long history and is still relevant in modern life [1]. People which are in the blast zone suffer a variety of injuries related to both blast wave (BW) influence and damage by additional factors [2]. The most vulnerable to the effects of BW are the brain, lungs and eardrum [3, 4]. While moderate to severe blast-induced traumatic brain injury (bTBI) is usually diagnosed quickly, mild trauma is more difficult to diagnose [5]. Modern research shows that even mild bTBI has significant and often irreversible consequences. Cli-

nicians point to emotional disorders, anxiety, aggressiveness, depression, and memory impairment [6]. In connection with this, now experimental studies to establish biological (biochemical, molecular, cellular, tissue, functional, behavioral) markers of blast-induced brain injury are gaining momentum [7]. In particular, on the 1st day of the post-traumatic period, macroscopic cerebral edema was detected but the hemorrhage was not determined [8]. Microscopically, blood-brain barrier (BBB) damage, changes in neuronal density, axonal damage and progressive myelin loss are detected [2, 9, 10]. In the long-term period, the development of neurodegeneration is observed [11]. This, in turn, leads to cognitive impairment and

worsens life quality of people with bTBI. There is evidence that after the primary brain damage by BW the oxidative stress develops and this is also a factor of damaging both the BBB and neurons [12]. Also, various scientific papers have shown that individual brain structures have different sensitivity to the effects of BW, but damage to the BBB is present in all structures [8, 12, 13].

In our opinion, given that an explosive shock wave is a process of transmission of vibrations with overpressure at the wave front, which physically changes the state and particles of the medium in which it propagates, pathomorphological data, in particular at the histopathological and ultrastructural levels, are needed to determine the primary biomarkers of bTBI immediately after exposure of the blast wave. An objective pathomorphologic picture of the explosive shock wave impact of appropriate intensity, frequency, and overpressure parameters can be obtained only in an experiment. Also there is an urgent need to develop a standardized assessment scale for brain damage in order to compare it with other blast wave results and parameters [14]. In clinical practice, to objectify the consequences of traumatic brain injury, an assessment of focal and diffuse changes by neuroimaging methods (computed tomography, positron emission tomography, magnetic resonance imaging) with the calculation of the Evans cerebro-ventricular index is used [15].

Purpose – to establish and study histopathological and ultrastructural changes in the rats brain after exposure to an air blast wave.

MATERIALS AND METHODS OF RESEARCH

For the experiment, 18 male Wistar rats weighing 220-270 g were used. Rats were randomly divided into two groups: sham (n=9) and experimental (n=9). The animals were kept in standard conditions and on a standard diet in the vivarium of the Dnipro State Medical University. All manipulations were carried out according to a pre-designed and approved plan. Procedures were in compliance with the rules of the current legislation: Law of Ukraine "On Protection of Animals from Cruelty" No. 3447-IV of 21.02.2006, Law of Ukraine "On Approval of the Procedure for Conducting Experiments and Experiments on Animals by Scientific Institutions" No. 249 of 01.03.2012, "European Convention for the Protection of Vertebrate Animals Used for Research and Other Scientific Purposes (ETS 123)" (1986), "Directive 2010/63/EU of the European Parliament and of the Council of 22 September 2010 on the protection of animals used for scientific purposes", recommendations, as well as the Guide for the Care and Use of Laboratory Animals and ARRIVE [16, 17]. Every effort was made to minimize both the suffering and the number of animals, as evidenced by the extract from the minutes of the meeting of the Biomedical Ethics Committee of the Dnipro State Medical University No. 3 (2.11.2021).

The animals of the experimental group were anesthetized with halothane and tightly fixed in a horizontal position on the abdomen with the front part of the rat's muzzle at a distance of 5 cm from the opening of the device (Fig. 1).



Fig. 1. Position of the rat to the device

The blast wave was created by instantaneous (using an electromagnetic valve) opening a chamber filled with compressed air (up to 15 atm, i.e.,

≈1520 kPa). In our experiment, the blast wave was generated with an overpressure of 26-36 kPa using a device of our own design (Fig. 2) [18, 19].

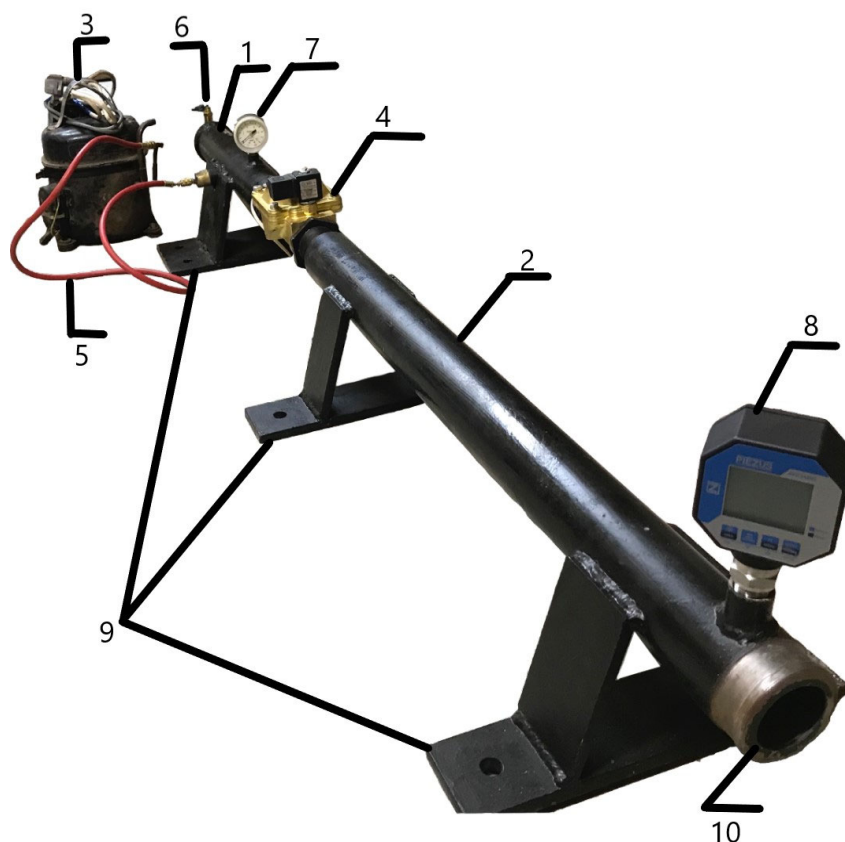


Fig. 2. Device for generating a blast wave: 1 – high pressure chamber, 2 – low pressure chamber, 3 – air compressor, 4 – electromagnetic valve, 5 – hose for supplying the air mixture, 6 – overpressure relief valve, 7 – pressure gauge for measuring static pressure, 8 – piezoelectric high-speed sensor for overpressure measurement, 9 – metal supports for fixing the device, 10 – muzzle part of the low pressure chamber

The amount of overpressure corresponded to the minimum limit of mild bTBI. No animal deaths were recorded during the experiment.

Animals of both groups were decapitated after preliminary anesthesia with halothane (Halothan, Hoechst AG, Germany) 1 hour after exposure to the pathological factor and the brain was removed for morphological examination. Next, frontal brain incisions were made, followed by immersion of the corresponding brain areas in a 10% solution of neutral formalin with an exposure time of 24 hours. After fixation, paraffin blocks were prepared, from which 3-5 μm thick sections were made on a Thermo HM 355S microtome (Thermo Scientific, Germany). Before staining, the sections were deparaffinized in xylene and rehydrated in decreasing concentration of isopropanol. Sections were stained with hematoxylin and eosin according to generally accepted standards of pathological procedures [20]. Microscopic

examination was carried out using a trinocular light-optical microscope "Primo Star Carl Zeiss" with a photographic output and lenses.

The experimental and sham rats brain fragments were taken from the frontal cortex, thalamus, and hippocampus and fixed with 2.5% glutaraldehyde solution. Postfixation of the material was performed in 1% OsO₄ buffer solution. The tissue was dehydrated with alcohol, and then the material was placed in Epon-812 (SPI-Pon™ 812 Epoxy Embedding Kit, USA) [19]. Ultrathin sections were made on an ultramicrotome UMTP-6M (SELMi, Ukraine). Visualization was performed using a transmission electron microscope TEM-100-01 (SELMi, Ukraine). Electron micrographs were obtained using the SEO-SCAN digital image processing system.

The assessment of the primary lesion of the brain substance was performed in points according to the developed rating scale (Table).

Scale for assessing primary histostructural lesions of the brain

Score	Type of damage	Damage description
1	Hemorrhage	Small-focal, local, intracerebral
	Rupture of brain tissue	Absent
2	Hemorrhage	Small-focal, multifocal or large-focal diffuse, intracerebral
	Rupture of brain tissue	Absent
3	Hemorrhage	Large-focal, multifocal or subarachnoid, intraventricular
	Rupture of brain tissue	Rupture of brain gray or white matter, regardless of the size of the tear

The results were compared between the sham and experimental groups.

To quantify the perivascular and pericellular edema in the frontal cortex and hippocampus, morphometric studies were performed using the ImageJ program. Digital images of histological specimens were saved in ipg format and transferred to the program interface. Using the software modules (plugins), Color Threshold, Analyze/Set Measurements/Measure, the % of the relative area of the edematous component was automatically determined on inverted black and white images.

Statistical analysis was performed using the software STATISTICA 6.1 (StatSoftInc., serial number AGAR909E415822FA). The hypothesis of normality of distribution among the studied quantitative traits was tested using the Shapiro-Wilk test. Subsequently, the arithmetic mean (M) and standard deviation (SD) were calculated. The Mann-Whitney U test was used to assess the differences between the sham and experimental

groups. The critical value of the statistical significance level (p) for the analysis was <5% (p<0,05) [21].

RESULTS AND DISCUSSION

We have studied the effects of a single exposure to an air shock wave with an overpressure of 31.6±4.8 kPa on the cortical (frontal cortex) and sub-cortical brain structures (hippocampus and thalamus) at the light-optical and ultrastructural levels. The amount of overpressure corresponded to the minimum limit of human concussion.

Macroscopic analysis showed that no hemorrhages were detected in and under the soft tissues of the rat head, as well as above and below the meninges. After a general evaluation of frontal histological sections of the brain at a magnification of x100, regional analysis of brain tissue was performed at magnifications of x100 and x200. The obtained micropreparations were compared with the corresponding brain regions of the sham rats (Fig. 3).

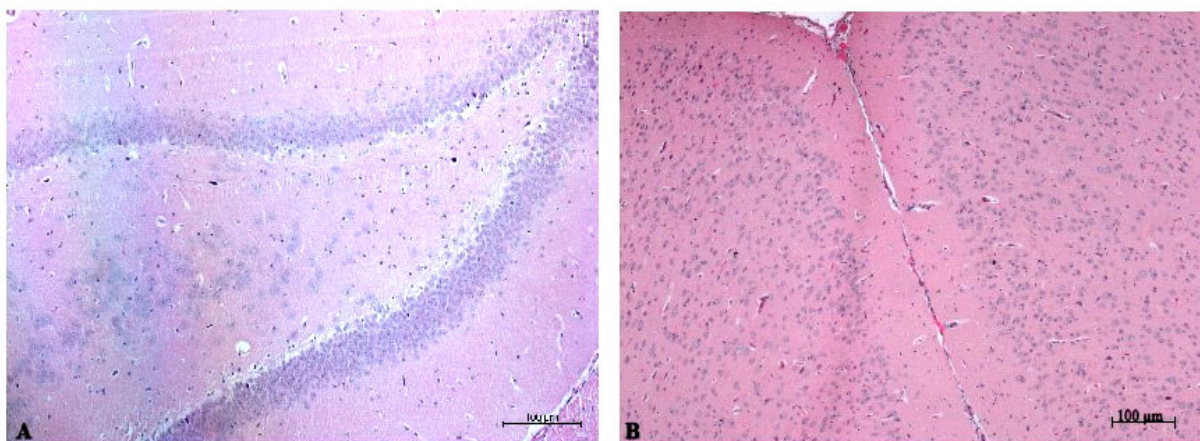


Fig. 3. Histological examination of the sham rats brain. Staining H&E.

A – hippocampus, magnification x100 (scale bar =100 µm), B – thalamus, magnification x100 (scale bar =100 µm)

During the examination of the detected injuries, the localization of the lesion, the type and nature of the injury were recorded. The most visual and permanent primary lesions during light microscopy

included small-focal multifocal hemorrhages, cerebral vascular ruptures, and microscopic ruptures of the brain substance (Fig. 4).

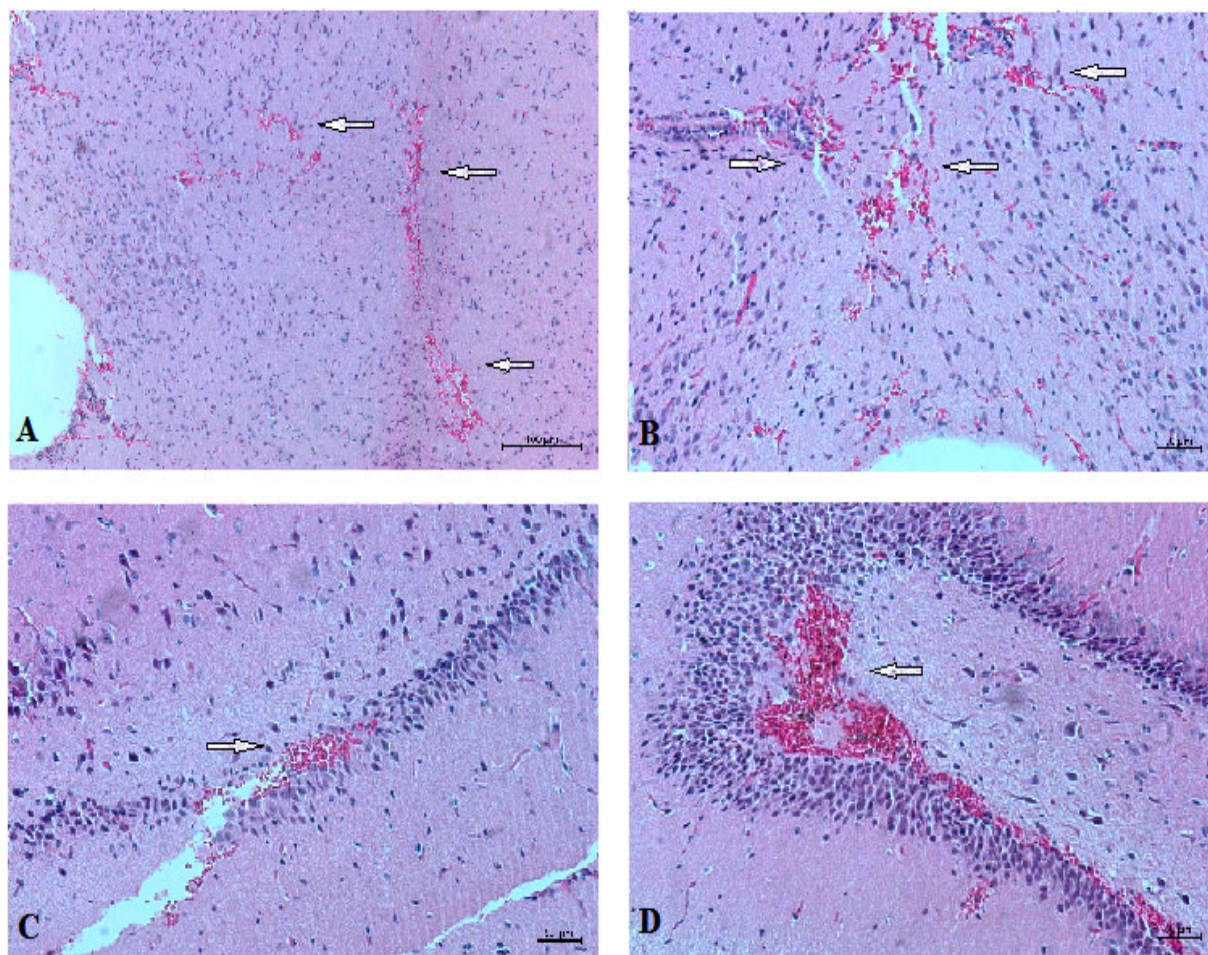


Fig. 4. Pathologic examination of the experimental rats brain — H&E:
A – thalamus, magnification x100 (scale bar =100 µm),
B – thalamus, magnification x100 (scale bar =50 µm),
C – thalamus, ventral hippocampus, magnification x200 (scale bar =50 µm),
D – ventral hippocampus, magnification x200 (scale bar =50 µm).
Ruptures in the brain's neuropil and hemorrhages are marked with white arrows

In our opinion, the nature and severity of hemorrhages depend on their distance from the ventricular system of the brain. The subependymal substance of the brain is one of the permanent localizations of hemorrhage foci after a blast wave. The paraventricular location of hemorrhages was characteristic of all experimental animals. This concerned both the walls of the lateral and 3rd ventricles. The damage degree of the areas adjacent to the cerebrospinal fluid system varied from petechial and group hemorrhages to ventricular wall rupture with paraventricular brain matter hemorrhagic imbibition. Less permanent and

less pronounced hemorrhages included vascular plexuses areas of the cerebrospinal fluid system of the brain and subpial spaces. Around the blood vessels, in the hippocampus, thalamus, and rarely in other brain structural formations, hemorrhages of a predominantly petechial nature were detected. The microscopic picture in all studied brain regions of rats 1 hour after exposure to BW showed extravasal accumulation of unchanged erythrocytes, vascular endothelial desquamation, capillary and brain tissue ruptures, and heterogeneity of neuronal staining (neurons with cytoplasmic hyper eosinophilia).

The brain substance microscopic examination showed that in almost all samples there was a significant plethora of venous vessels with the presence of erythrocyte stasis in the lumen of these vessels. In the arterial link, uneven blood filling with areas of narrowing was detected. The arteriole endothelial cells had an edematous appearance with explosion

into the vessels lumen. In the brain tissue around individual capillaries, arterioles and venules, the perivascular space contained red blood cells with clear contours. We also conducted an ultrastructural study using transmission electron microscopy and compared brain samples of the sham (Fig. 5) and experimental (Fig. 6) groups.

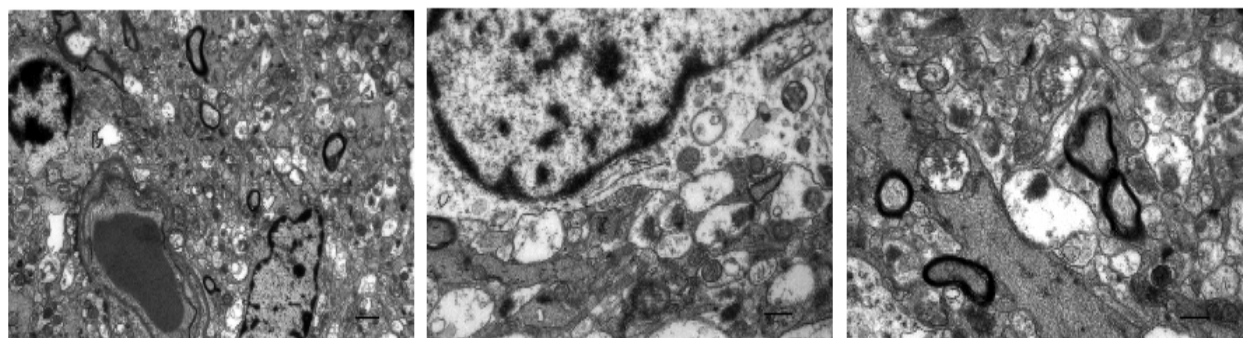


Fig. 5. Hemocapillary, neurons and brain processes of the sham rats. Electron micrograph. Scale bar =500 nm

At the ultrastructural level in rats of the experimental group, abnormalities at the level of the blood-brain barrier, the presence of perivascular edema, and petechial hemorrhages in the neuropil were recorded (Fig. 6).

According to the results of calculating damage index of primary histostructural changes in the brain (Table), significant ($p \leq 0.01$) differences were found in the experimental group (2.34 ± 0.5) compared with the sham group (0.89 ± 0.34) (Fig. 7).

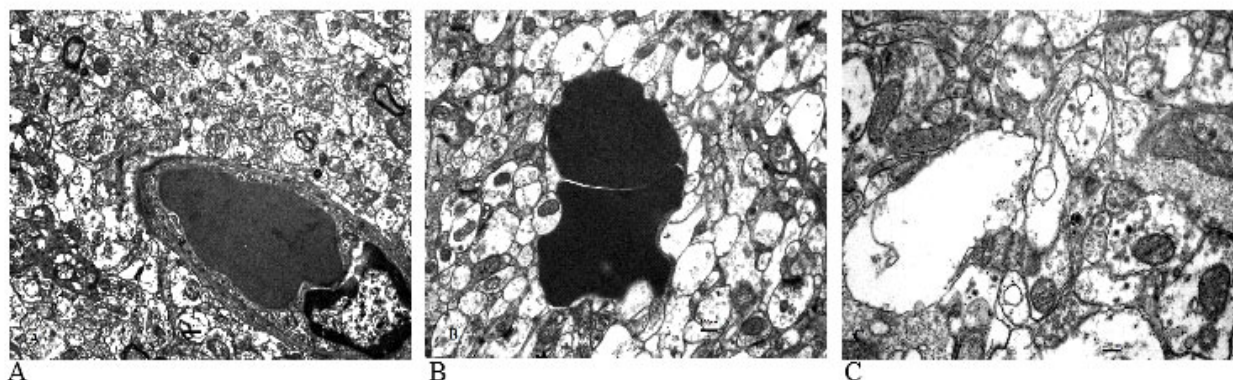
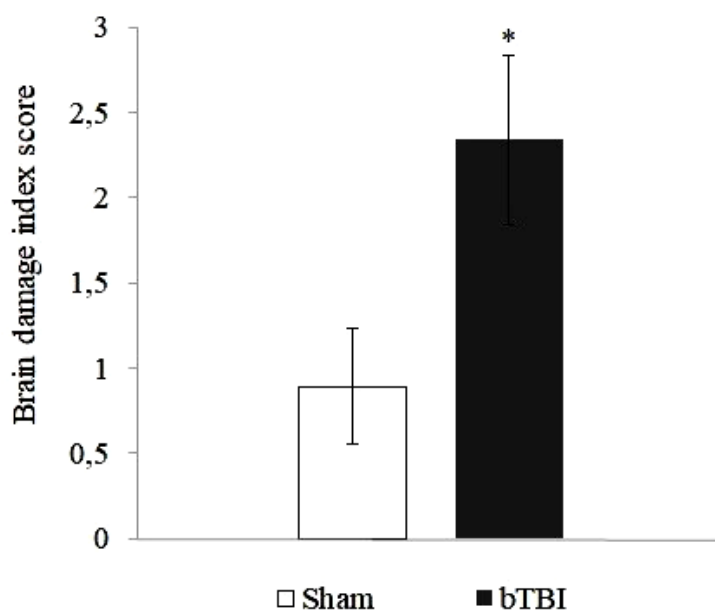


Fig. 6. Ultrastructural changes in the brain of rats of the experimental group. Electron micrograph. A – perivascular edema (hippocampus), B – petechial hemorrhage in the neuropil of the frontal cortex, C – pericellular edema (hippocampus). A, B: scale bar =500 nm; C: scale bar =200 nm

In no case there was a violation of the dura mater continuity. It should be noted that in relation to the median conditional line in the analysis of frontal brain slices, the degree and spread of damage (hemorrhages, brain tissue ruptures) were asymmetrical.

The relative area occupied by perivascular and pericellular edema within the cerebral cortex (Fig. 8 A, B) in the sham rats was $1.3 \pm 0.06\%$, in the experimental rats – $5.1 \pm 0.04\%$ ($p \leq 0.01$), in the hip-

pocampus (Fig. 8 C, D) of sham rats, the relative area of the edematous component was $1.9 \pm 0.05\%$, in the experimental rats – $4.7 \pm 0.04\%$ ($p \leq 0.01$). The differences in the calculated relative areas occupied by perivascular and pericellular edema within the cerebral cortex and hippocampus were statistically significant changes in the experimental group compared to the sham group.



Sham — sham group; bTBI – experimental group (* – $p \leq 0,01$).

Fig. 7. Scoring of primary histostructural lesions of the brain.
Brain damage index score - the brain damage index is expressed in conventional units

In scientific research, there are still conflicting views on the primary mechanisms that lead to brain damage after exposure to an air shock wave [22, 23].

We investigated early pathological effects (1 hour after bTBI) in the rats brain exposed to low-intensity

BW. Our results showed that even after a single exposure to low-intensity BW, pathological changes were detected not only at the ultrastructural level, but also at the light-optical level in the brain subcortical structures (thalamus, hippocampus).

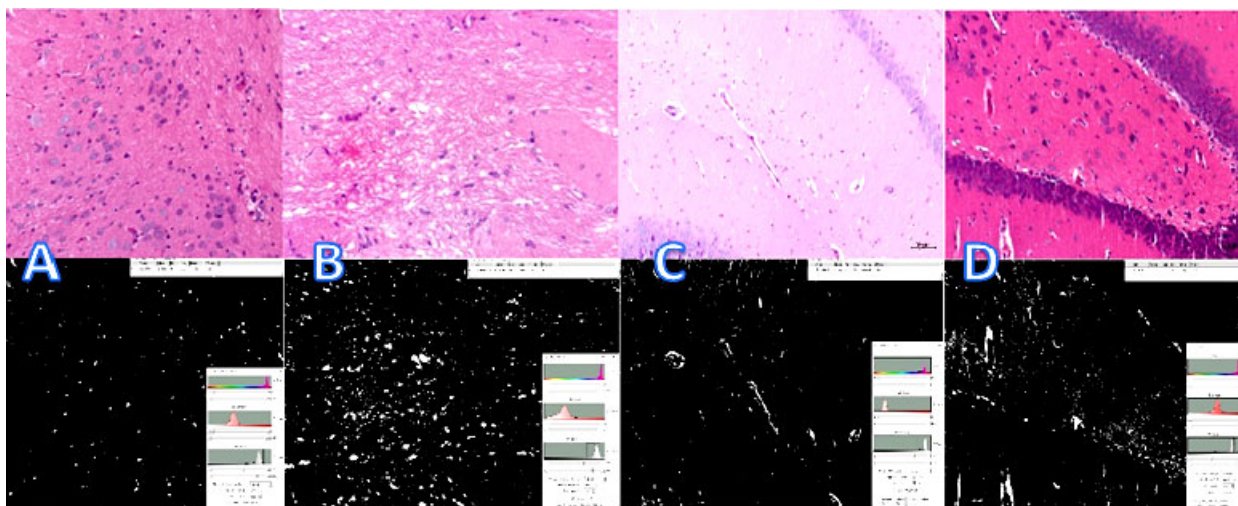


Fig. 8. Digital analysis of histological specimens of the cerebral cortex and hippocampus of sham and experimental rats using ImageJ plugins.
A – cerebral cortex of the sham rat, B – cerebral cortex of the experimental rat,
C – hippocampus of the sham rat, D – hippocampus of the experimental rat

These changes can be explained only by the direct effect on the vascular membranes with the formation of diffuse damage to the vascular component of the brain, which is the most vulnerable after exposure to BW.

In the aforementioned study, the effect of BW was associated with the destruction of brain vessels, the release of red blood cells outside the blood vessels and the appearance of hypereosinophilic swollen

neurons. In the dynamics of the study, the consequences of BW were neurodegenerative changes, activation of astrocytes, and microglia. In contrast to this study, we used much smaller physical parameters of the air shock wave with no less destructive effects on brain tissue, in particular on cortical and subcortical structures. The interaction of BW with the brain is the trigger for a sequence of mechanisms that lead to neuronal dysfunction, blood-brain barrier, which in turn leads to interstitial edema, tissue acidosis, and oxygenation disorders. The traumatic lesions in the relevant brain regions identified during the study are compared with specific molecular changes, namely a significant increase in inflammatory markers (interferon, interleukin-6), proteins (GFAP), which were recorded during the simulation of bTBI in rats in the hippocampus, prefrontal cortex, amygdala areas [24].

In addition to vascular damage, areas of destruction with the formation of crack-like ruptures in the brain tissue were found. We think, this is also a consequence of the interaction of BW with the brain tissue, accompanied by its deformation due to shear, tension and compression, which agrees with the other researchers' opinion [25]. The modern literature also describes cases of brain substance ruptures after exposure to BW in experimental conditions [26]. The detected microruptures were accompanied by a displacement of the hippocampal layer and its separation. There was an opinion that the ruptures in the brain matter could be related to the location of blood vessels, but these assumptions were not confirmed.

Until recently, the question of the leading mechanism of primary morphological changes due to bTBI has remained controversial and widely discussed [27, 28]. Among these issues, the biomechanics of bTBI attracts the most attention due to the increasing number of such patients and the problems of differential diagnosis with traumatic brain injury of other origin [29, 30, 31]. As a result of the direct impact of BW on the brain, there are main hypotheses of primary explosive changes [32], which include the transmission hypothesis (impact of the shock wave on the brain through the natural openings of the skull and transmission of the shock wave to the brain due to changes in pressure in the chest and abdominal cavity), acceleration hypothesis (sharp displacement of brain structures), cavitation hypothesis (formation of cavitation cavities in brain structures and their rupture during a sudden pressure drop) [33, 34].

We took into account the detected traumatic injuries in the brain substance when quantifying the primary effects of trauma according to the proposed evaluation scale. The use of such modified injury

assessment scales is a necessary tool in the diagnosis and treatment of any injury. To develop a scale for assessing primary craniocerebral injuries after exposure to an air blast wave, there were taken described primary traumatic injuries of the membranes and brain substance after on blow to an unfixed head with a blunt object bigger in size [30].

CONCLUSIONS

1. A morphological algorithm for assessing primary histostructural intracranial brain injuries and their consequences after exposure to an air shock wave is proposed.

2. The detected injuries, namely hemorrhages in the brain substance and ruptures in the blood vessels walls and brain tissue were caused by the direct traumatic effect of the air shock wave.

3. In the acute post-traumatic period, histopathological and ultrastructural changes in the brain can manifest as changes in neurons (neurons with cytoplasmic hyper eosinophilia and edema) and changes in the blood-brain barrier (capillary ruptures) and are accompanied by perivascular multi- and small-focal hemorrhages, neuropil ruptures, edema of the pericellular and perivascular spaces, the latter in total can be considered as biomarkers of primary traumatic changes after exposure to an air shock wave.

ACKNOWLEDGEMENTS. We thank the Rector of Dnipro State Medical University, Academician of the National Academy of Medical Sciences of Ukraine, Professor Tetiana Pertseva for her support in research, providing the material and technical base of the university, Professor Ihor Tverdokhlib for his help in making electron images, and Professor Ihor Shponka for his advice on brain pathomorphology.

Contributors:

Kozlov S.V. – conceptualization, writing, methodology, verification;

Kozlova Yu.V. – data curation, fundraising, visualization, investigation, review and editing;

Bondarenko N.S. – resources, formal analysis, review and editing;

Bondarenko O.O. – software, supervision, and project administration.

Funding. This work was carried out as part of the planned initiative research topic of the Department of Pathological Anatomy, Forensic Medicine and Pathological Physiology of the Dnipro State Medical University "Mechanisms of formation of changes in the central nervous system after exposure to extreme factors", state registration No. 0120U105394.

Conflict of interests. The authors declare no conflict of interest.

REFERENCES

1. Guillaume-Correa F, Pickrell AM, Vande Vord PJ. The imbalance of astrocytic mitochondrial dynamics following blast-induced traumatic brain injury. *Biomedicines*. 2023;11(2):329. doi: <https://doi.org/10.3390/biomedicines11020329>
2. Nonaka M, Taylor WW, Bukalo O, et al. Behavioral and myelin-related abnormalities after blast-induced mild traumatic brain injury in mice. *J Neurotrauma*. 2021;38(11):1551-71. doi: <https://doi.org/10.1089/neu.2020.7254>
3. Ou Y, Clifton BA, Li J, et al. Traumatic brain injury induced by exposure to blast overpressure via ear canal. *Neural Regen Res*. 2022;17(1):115-21. doi: <https://doi.org/10.4103/1673-5374.314311>
4. Huwer H, Hadizamani Y, Moehrlen U, et al. Ex Vivo pulmonary oedema after In Vivo blast-induced rat lung injury: time dependency, blast intensity and beta-2 adrenergic receptor role. *Biomedicines*. 2022;10(11):2930. doi: <https://doi.org/10.3390/biomedicines10112930>
5. Barnes DE, Byers AL, Gardner RC, et al. Association of mild traumatic brain injury with and without loss of consciousness with dementia in US military veterans. *JAMA Neurol*. 2018;75(9):1055-61. doi: <https://doi.org/10.1001/jamaneurol.2018.0815>
6. Griffiths DR, Law LM, Young C, et al. Chronic cognitive and cerebrovascular function after mild traumatic brain injury in rats. *J Neurotrauma*. 2022;39(19-20):1429-41. doi: <https://doi.org/10.1089/neu.2022.0015>
7. Race NS, Andrews KD, Lungwitz EA, et al. Psychosocial impairment following mild blast-induced traumatic brain injury in rats. *Behav Brain Res*. 2021;412:113405. doi: <https://doi.org/10.1016/j.bbr.2021.113405>
8. Shi QX, Chen B, Nie C, et al. A novel model of blast induced traumatic brain injury caused by compressed gas produced sustained cognitive deficits in rats: involvement of phosphorylation of tau at the Thr205 epitope. *Brain Res Bull*. 2020;157:149-61. doi: <https://doi.org/10.1016/j.brainresbull.2020.02.002>
9. Kawoos U, Abutarboush R, Gu M, et al. Blast-induced temporal alterations in blood-brain barrier properties in a rodent model. *Sci Rep*. 2021;11(1):5906. doi: <https://doi.org/10.1038/s41598-021-84730-8>
10. Bishop R, Won SJ, Irvine KA, et al. Blast-induced axonal degeneration in the rat cerebellum in the absence of head movement. *Sci Rep*. 2022;12(1):143. doi: <https://doi.org/10.1038/s41598-021-03744-4>
11. Pavlovic D, Pekic S, Stojanovic M, Popovic V. Traumatic brain injury: neuropathological, neurocognitive and neurobehavioral sequelae. *Pituitary*. 2019;22(3):270-82. doi: <https://doi.org/10.1007/s11102-019-00957-9>
12. Kuriakose M, Younger D, Ravula AR, et al. Synergistic role of oxidative stress and blood-brain barrier permeability as injury mechanisms in the acute pathophysiology of blast-induced neurotrauma. *Sci Rep*. 2019;9(1):7717. doi: <https://doi.org/10.1038/s41598-019-44147-w>
13. Schwab N, Leung E, Hazrati LN. Cellular senescence in traumatic brain injury: evidence and perspectives. *Front Aging Neurosci*. 2021;13:742632. doi: <https://doi.org/10.3389/fnagi.2021.742632>
14. Yalciner BZ, Kandemir M, Taskale S, et al. Modified visual magnetic resonance rating scale for evaluation of patients with forgetfulness. *Can J Neurol Sci*. 2019;46(1):71-8. doi: <https://doi.org/10.1017/cjn.2018.333>
15. Sparks P, Lawrence T, Hinze S. Neuroimaging in the diagnosis of chronic traumatic encephalopathy: A systematic review. *Clin J Sport Med*. 2020;30,1:S1-S10. doi: <https://doi.org/10.1097/JSM.0000000000000541>
16. National Advisory Committee for Laboratory Animal Research. Guidelines on the care and use of animals for scientific purpose. Singapore; 2022. 145 p.
17. Percie du Sert N, Hurst V, Ahluwalia A, et al. The ARRIVE guidelines 2.0: updated guidelines for reporting animal research. *PLoS Biol*. 2020;18(7):e3000410. doi: <https://doi.org/10.1371/journal.pbio.3000410>
18. Kozlova YuV, Abdul-Ohly LV, Kosharnyi AV, Kytova IV, Korzachenko MA, inventors. [Device for studying the effect of the shock wave of an explosion on the body]. Patent Ukraine U202100358. 2021 Mar 24. Ukrainian.
19. Elder GA, Gama Sosa MA, De Gasperi R, et al. The neurovascular unit as a locus of injury in low-level blast-induced neurotrauma. *Int J Mol Sci*. 2024;25(2):1150. doi: <https://doi.org/10.3390/ijms25021150>
20. Bagriy MM, Dibrova VA, Popadynets OG, Grischuk MI. [Methods of morphological research]. Vinnytsia: Nova knyha; 2016. 328 p. Ukrainian.
21. Danilov VY. [Statistical data processing: tutorial]. Kyiv; 2019. 156 p. Ukrainian.
22. Logsdon AF, Lucke-Wold BP, Turner RC, et al. Low-intensity blast wave model for preclinical assessment of closed-head mild traumatic brain injury in rodents. *J Vis Exp*. 2020;165:10.3791/61244. doi: <https://doi.org/10.3791/61244>
23. Gama Sosa MA, De Gasperi R, Pryor D, et al. Late chronic local inflammation, synaptic alterations, vascular remodeling and arteriovenous malformations in the brains of male rats exposed to repetitive low-level blast overpressures. *Acta Neuropathol Commun*. 2023;11(1):81. doi: <https://doi.org/10.1186/s40478-023-01553-6>
24. Ma X, Aravind A, Pfister BJ, et al. Animal models of traumatic brain injury and assessment of injury severity. *Mol Neurobiol*. 2019;56(8):5332-45. doi: <https://doi.org/10.1007/s12035-018-1454-5>
25. Przekwas A, Garimella HT, Tan XG, et al. Biomechanics of blast TBI with time-resolved consecutive primary, secondary, and tertiary loads. *Mil Med*. 2019;184:195-205. doi: <https://doi.org/10.1093/milmed/usy344>
26. Chen B, Tjahja J, Malla S, et al. Astrocyte viability and functionality in spatially confined microcavitation zone. *ACS Appl Mater Interfaces*. 2019;11(5):4889-99. doi: <https://doi.org/10.1021/acsami.8b21410>
27. Fievisohn E, Bailey Z, Guettler A, VandeVord P. Primary blast brain injury mechanisms: current knowledge, limitations, and future directions. *J Biomech Eng*. 2018;140(2). doi: <https://doi.org/10.1115/1.4038710>

28. Russell AL, Richardson MR, Bauman BM, et al. Differential responses of the HPA axis to mild blast traumatic brain injury in male and female mice. *Endocrinology*. 2018;159(6):2363-75. doi: <https://doi.org/10.1210/en.2018-00203>
29. Belding JN, Englert RM, Fitzmaurice SJ, et al. Potential health and performance effects of high-level and low-level blast: a scoping review of two decades of research. *Front Neurol*. 2021;12:628782. doi: <https://doi.org/10.3389/fneur.2021.628782>
30. Friedman LK, Peng H, Zeman RJ. Cannabidiol reduces lesion volume and restores vestibulomotor and cognitive function following moderately severe traumatic brain injury. *Exp Neurol*. 2021;346:113844. doi: <https://doi.org/10.1016/j.expneurol.2021.113844>
31. Gallo V, Motley K, Kemp SPT, et al. Concussion and long-term cognitive impairment among professional or elite sport-persons: a systematic review. *J Neurol Neurosurg Psychiatry*. 2020;91(5):455-68. doi: <https://doi.org/10.1136/jnnp-2019-321170>
32. Ratliff WA, Mervis RF, Citron BA, et al. Effect of mild blast-induced TBI on dendritic architecture of the cortex and hippocampus in the mouse. *Sci Rep*. 2020;10(1):2206. doi: <https://doi.org/10.1038/s41598-020-59252-4>
33. Han EX, Fernandez JM, Swanberg C, et al. Longitudinal auditory pathophysiology following mild blast-induced trauma. *J Neurophysiol*. 2021;126(4):1172-89. doi: <https://doi.org/10.1152/jn.00039.2021>
34. Marsh JL, Bentil SA. Cerebrospinal fluid cavitation as a mechanism of blast-induced traumatic brain injury: a review of current debates, methods, and findings. *Front Neurol*. 2021;12:626393. doi: <https://doi.org/10.3389/fneur.2021.626393>

Стаття надійшла до редакції 16.10.2023;
затверджена до публікації 18.02.2024

