





**Yasmin L. Alsaadi**,   
**Bassam K. Abdul Ameer**,   
**Ban Jasim Mohamad**\*,   
**Faiza Kathum Omran** 

## THE IMPACT OF SUDAFED ON SPLEEN OF ALBINO MICE

University of Baghdad  
Al-Jadriya, Baghdad, Iraq  
Багдадський університет  
Аль-Джадрія, Багдад, Ірак  
e-mail: banjasimmohamef@gmail.com

*Цитування: Медичні перспективи. 2024. Т. 29, № 4. С. 66-73*

*Cited: Medicni perspektivi. 2024;29(4):66-73*

**Key words:** *sympathomimetic amines, toxicity, side effect, pseudoephedrine, energizers*

**Ключові слова:** *симпатоміметичні аміни, токсичність, побічна дія, псевдоефедрин, енергетики*

**Abstract.** *The impact of Sudafed on spleen of albino mice. Yasmin L. Alsaadi, Bassam K. Abdul Ameer, Ban Jasim Mohamad, Faiza Kathum Omra. Pseudoephedrine (PSE), often known as Sudafed, belongs to a class of medications known as sympathomimetic amines, which affect the digestive system, respiratory system, and cardiovascular system. This drug has a long history of medical use; it is helpful in treating symptoms of the common cold and flu, sinusitis, asthma, and bronchitis. Due to its central nervous system (CNS) stimulant properties and structural similarity to amphetamine, it is also used for non-medical purposes such as doping agent, to increase focus, and as a substance that gets rid of exhaustion and drowsiness. Nevertheless only a few studies, backed up its impact on solid abdominal organs. The aim of this task is to investigate the effect of some dosages of PSE medication on the histology of albino mice's spleens. The current study included 18 albino mice grouped into 2 groups: control (3 mice), and acute group (15 mice). The acute group was further divided into five subcategories with 3 mice in each, and the animals received a single intraperitoneal injection of 0.3 ml of each of the following concentrations of drug for 24 hours: 500 mg/kg, 250 mg/kg, 125 mg/kg, 62.52 mg/kg, and 31.24 mg/kg. After the mentioned period, the mice of all subgroups were sacrificed and the spleens were removed, processed, sectioned and stained for histological analysis. Results showed that the amount of PSE administered at 500 mg/kg caused considerable sago spleen, numerous amyloid depositions in peripheral zone, sinusoidal red pulp congestion, and hyperplasia inside the germinal center. While less powerful effects or no detectable pathological alterations were seen at lower doses (125, 62.52, and 31.24 mg/Kg). This investigation demonstrated some pathological effects of this drug on spleen of albino mice at higher doses as compared to lower doses and control which recommends the use of minimal doses of PSE to avoid its adverse effects.*

**Реферат.** *Вплив Судафеду на селезінку мишей-альбіносів. Ясмін Л. Альсааді, Бассам К. Абдул Амір, Бан Джасім Мохамад, Файза Катум Омра. Псевдоефедрин, часто відомий як Судафед, належить до класу ліків, що називаються симпатоміметичні аміни, які впливають на травну систему, дихальну систему та серцево-судинну систему. Цей препарат має довгу історію медичного використання; він корисний для лікування симптомів застуди та грипу, синуситу, астми та бронхіту. Завдяки своїм стимулювальним властивостям щодо центральної нервової системи і структурній подібності до амфетаміну він також використовується в немедичних цілях, таких як допінг, для підвищення концентрації уваги та як речовина, що позбавляє від виснаження та сонливості. Проте лише кілька досліджень підтвердили його вплив на тверді органи черевної порожнини. Метою цієї роботи є дослідження впливу певних доз препарату псевдоефедрину на гістологію селезінки мишей-альбіносів. Поточне дослідження включало 18 мишей-альбіносів, розподілених на 2 групи: контрольну (3 миші) та гостру групу (15 мишей). Гостру групу розподіляли на п'ять підкатегорій по 3 миші в кожній, і тварини отримували одноразову внутрішньочеревну ін'єкцію 0,3 мл кожної з таких концентрацій препарату протягом 24 годин: 500 мг/кг, 250 мг/кг, 125 мг/кг, 62,52 мг/кг і 31,24 мг/кг. Після зазначеного періоду мишей усіх підгруп забивали, а селезінку видаляли, обробляли, розрізали та фарбували для гістологічного аналізу. Результати показали, що кількість псевдоефедрину, введена в дозі 500 мг/кг, спричинила значне саго селезінки, численні відкладення амлоїду в периферійній зоні, застій червоної синусоїдальної пульпи та гіперплазію всередині зародкового центру. Водночас за менших доз (125, 62,52 і 31,24 мг/кг) спостерігалися менш потужні ефекти або відсутність виявлених патологічних змін. Це дослідження продемонструвало деякі патологічні ефекти цього препарату на селезінку мишей-альбіносів у вищих дозах порівняно з нижчими дозами та контролем, що дозволяє рекомендувати використання мінімальних доз псевдоефедрину, щоб уникнути його несприятливих ефектів.*

Sudafed, (Pseudoephedrine, PSE) and Ephedrine (E) are alkaloids derived from various species of *Ephedra spp.* of the Ephedraceae family. PSE is a drug used in treating symptoms of the common cold and flu, sinusitis, asthma, and bronchitis. Due to its central nervous system (CNS) stimulant properties and structural similarity to amphetamine, it is also used for non-medical purposes. Nowadays, they are also used as stimulants, the so-called energizers, and as agents reducing appetite, body weight and increasing energy consumption. They are popular with bodybuilders, athletes, schoolchildren and students [1, 2]. The principal mechanism by which pseudoephedrine achieves its effects is by displacing the norepinephrine (noradrenaline) from the storage vesicles in the presynaptic neurons; then, it is released into the neuronal synapse and becomes available to activate the alpha and beta postsynaptic adrenergic receptors [3, 4].

The sympathomimetic group of drugs increases the peripheral vascular tone, respiratory stimulation, bronchial tube dilation, pupillary dilation, and relaxation of the smooth muscles of the gastrointestinal tract [5]. The peculiarity of selective alpha2-adrenergic agonists is that when taken orally, misused or overdosed, they lose their selectivity for the target receptor. As a result, the drug causes acute poisoning and most often this effect occurs in children and adolescents. The symptoms are manifested by hypothermia, skin pallor, bradycardia, arterial hypotension, profuse sweating, and acrocyanosis. Imidazole receptors and new opportunities: It is assumed that toxic effect of topical decongestants occurs not only by activation of alpha2-adrenergic receptors, but also through their influence on the selective imidazole receptors [6, 7]. Pseudoephedrine has a stimulant effect and can be used to make the drug methamphetamine (meth; crystal meth). It is usually only handed out by pharmacists from ‘behind the counter’, but it is important to be aware of its stimulant and possible addictive nature [8]. Pseudoephedrine acts directly on both alpha- and, to a lesser degree, beta-adrenergic receptors. Through direct action on alpha-adrenergic receptors in the mucosa of the respiratory tract, pseudoephedrine produces vasoconstriction. Pseudoephedrine relaxes bronchial smooth muscle by stimulating beta 2-adrenergic receptors. Like ephedrine, pseudoephedrine releasing norepinephrine from its storage sites being, an indirect effect. This is its main and direct mechanism of action. The displaced noradrenaline is released into the neuronal synapse where it is free to activate the postsynaptic adrenergic receptors [9].

In February 2014, the French Otorhinolaryngology Society, stated that vasoconstrictors “involve a risk of stroke and severe neurological effects” and that they “are often too risky for use against a simple cold [10].

More common side effects include nerviness, restlessness and trouble in sleeping. While less common side effects are difficult or painful urination, dizziness or lightheadedness, fast or pounding heartbeat, headache, increased sweating, nausea or vomiting, trembling, unusual paleness and weakness [11].

Overall, the reviews showed that the effect of pseudoephedrine is dose dependent. But none of the reviewed studies showed histologic effect on spleen with different doses of the drug. The aim of the study is to investigate the toxic effect of some doses of this drug on histology of spleen of albino mice.

#### MATERIALS AND METHODS OF RESEARCH

Overall eighteen, six-week-old male mice, weight 20-25 gm were used in this study and kept under standardized environmental conditions; constant temperature, moisture and with a 12-hr. light regime without stress factors. Mice were allowed to take laboratory food and water. Mice were randomized into two groups, and treatment was carried out as follow:

**I. Control Group** – contains 3 mice, got standardized lab food and water without treatment.

**II. Acute group** – contains 15 mice, divided into 5 subgroups, 3 mice in each, and received a single intraperitoneal injection (after determination of lethal 50 dose, LD50) as following:

- Subgroup 1 (G1): Injected with 0.3 ml (500 mg/kg)
- Subgroup 2 (G2): Injected with 0.3 ml (250 mg/kg)
- Subgroup 3 (G3): Injected with 0.3 ml (125 mg/kg)
- Subgroup 4 (G4): Injected with 0.3 ml (62.52 mg/kg)
- Subgroup 5 (G5): Injected with 0.3 ml (31.24 mg/kg)

After 24 hours of injection, all mice were observed behaviorally and morphologically, and notes were recorded. Then, the mice were euthanized; spleens were carefully removed and fixed in 4% buffered formaldehyde solution, dehydrated in increasing series of alcohol, and cleared in xylene. Next, the fixed biopsies were embedded in paraffin and cut into 5 µm slices. The slides were mounted on glass slides and stained with hematoxylin and eosin according to *Hematoxylin & Eosin Protocol for Leica ST5020 Automated Stainer* [12], and being ready for histological analysis. The sections had been examined below a compound microscope.

The College of Science Ethics committee approved the research proposal to be conducted in the presented form. None of the investigator and co-investigator participating in this study took part in the decision-making and voting procedure for this study. This Ethics committee is working in accordance with College of Science guidelines on biomedical research, including the document number CSEC/01223/00146 in Dec. 20, 2023.




**RESULTS AND DISCUSSION**

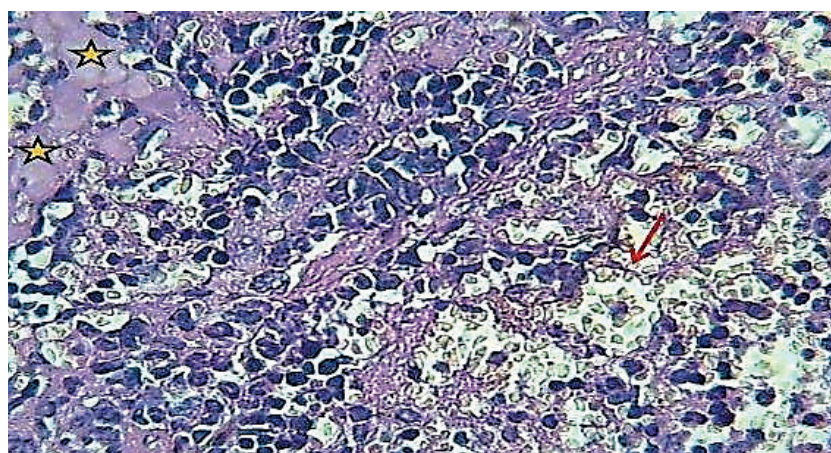
**Histological changes of spleen in acute group.**

Using 500 mg/kg Sudafed intraperitoneally, spleen sections showed the following changes: moderate sago spleen with numerous amyloid depositions in peripheral zone, sinusoidal congestion of red pulp and hyperplasia within germinal center (Fig. 1a, b). Moreover, sever splenic hemorrhage & sinusoidal dilation

with hyperplasia of lymphoid follicles were noticed in this dose (Fig. 2). The lower dose (250 mg/Kg) revealed sinusoidal dilation & sinusoidal congestion of red pulp, partial effacement of some lymphoid follicles with marked tissue depletion and inflammatory infiltrates (Fig. 3a, b, c). Lower doses (125, 62.52 and 31.24 mg/kg) revealed less prominent effect or no significant pathological changes as shown in (Fig. 4 a-e).

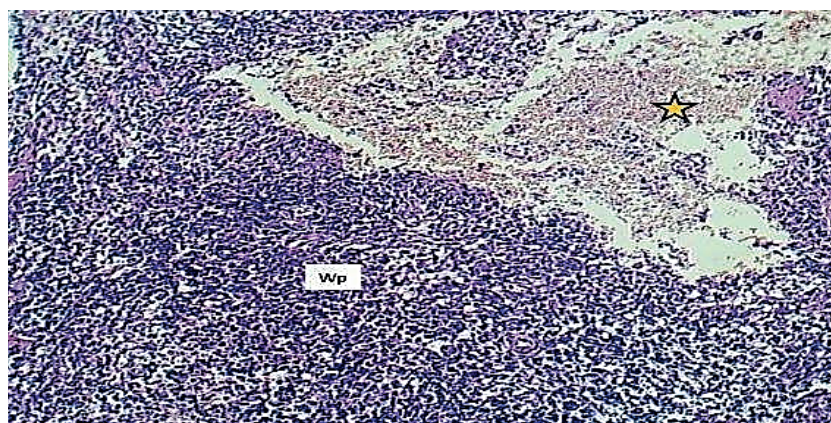


1a.




1b.

**Fig. 1.** Section of spleen (500 mg/kg Sudafed). 1a. – moderate sago spleen with numerous amyloid depositions in peripheral zone (Asterisks), sinusoidal congestion of red pulp (Red arrow), hyperplasia within germinal center (black arrow). H and E stain 40x. 1b. – amyloid depositions in peripheral zone (Asterisks), sinusoidal congestion of red pulp (Red arrow). H and E stain 400x

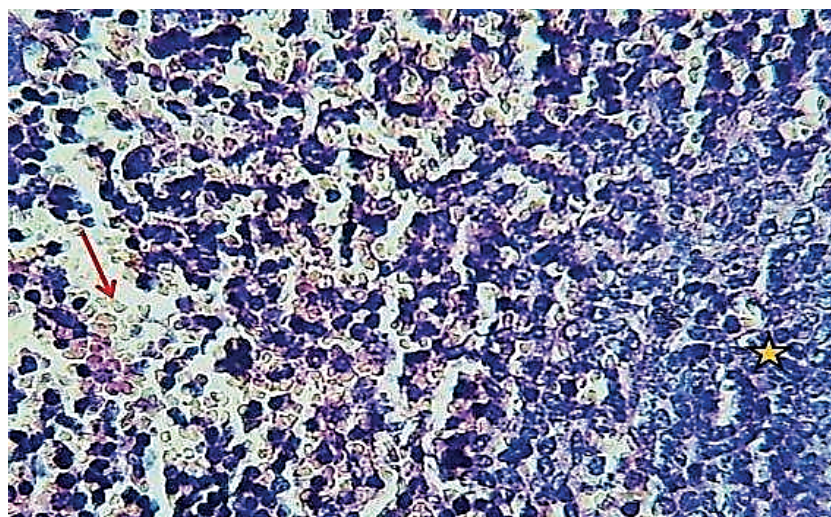


**Fig. 2.** Section of spleen (500mg/kg Sudafed) shows: sever splenic hemorrhage and sinusoidal dilation (Asterisk) with hyperplasia of lymphoid follicles (Wp). H and E stain 100x

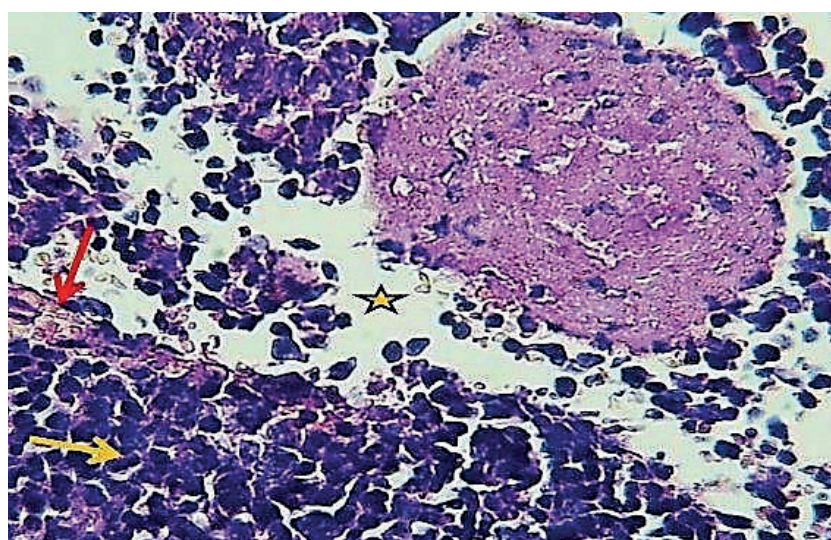




3a.



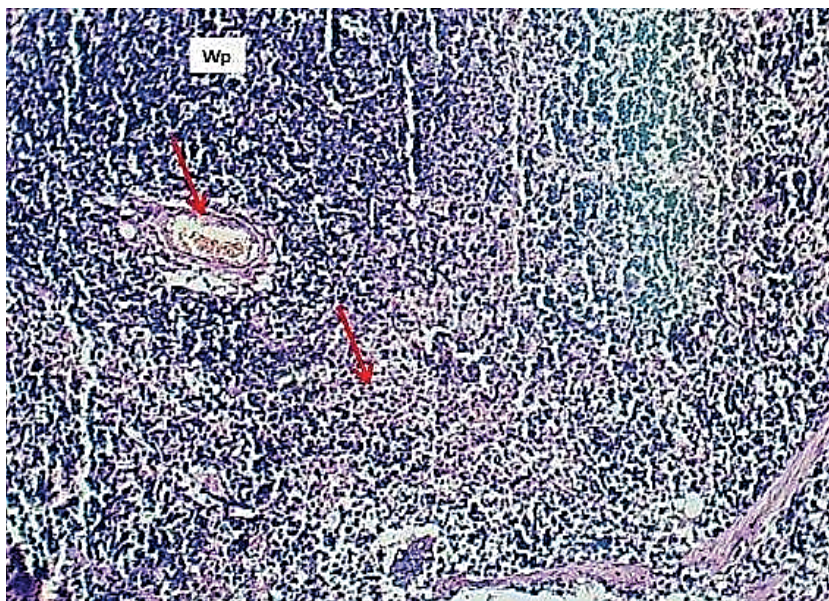
3b.



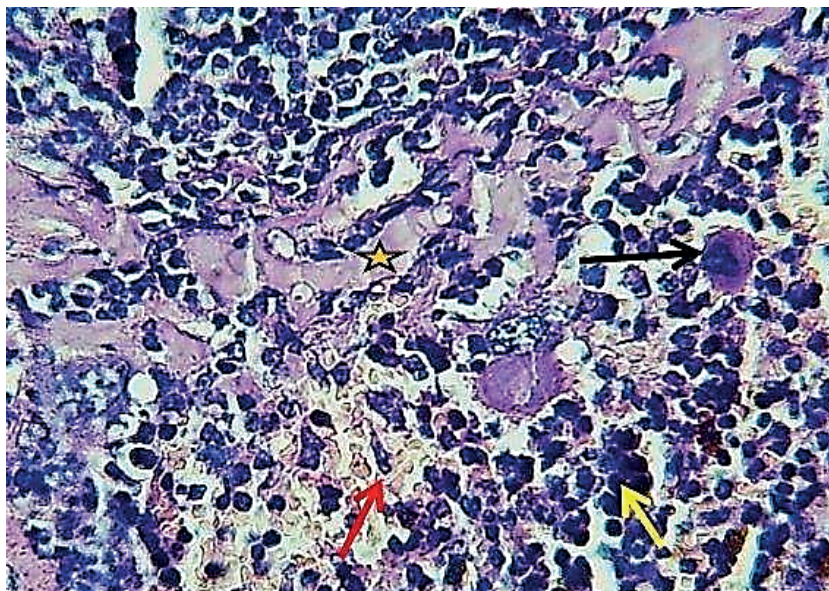
3c.

**Fig. 3. Section of spleen(250 mg/kg of Sudafed). 3a. – sinusoidal dilation (Asterisk) and sinusoidal congestion (Red arrows) with normal lymphoid follicles (Wp). H and E stain 40x; 3b. – sinusoidal congestion (Red arrows) and normal cyto ar chitecture of per ipher al zone of follicle (asterisk). H and E stain 400x; 3c. – partial effacement of some lymphoid follicles with marked tissue depletion (Asterisks) and sinusoidal congestion of red pulp (Red arrow) & inflammatory infiltrates (yellow arrows). H and E stain 400x**

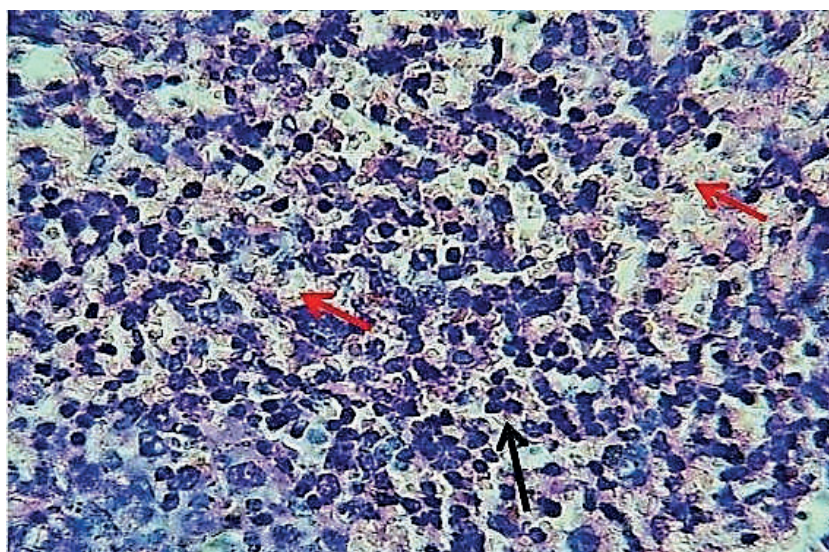




4a.

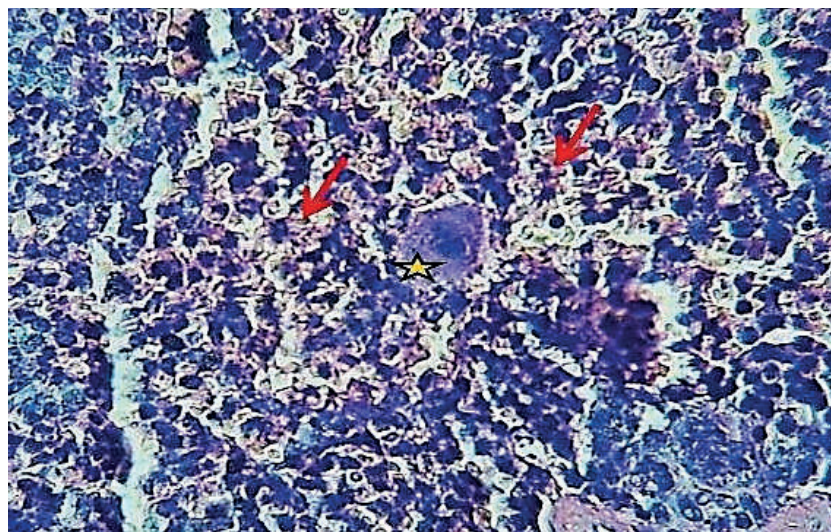


4b.

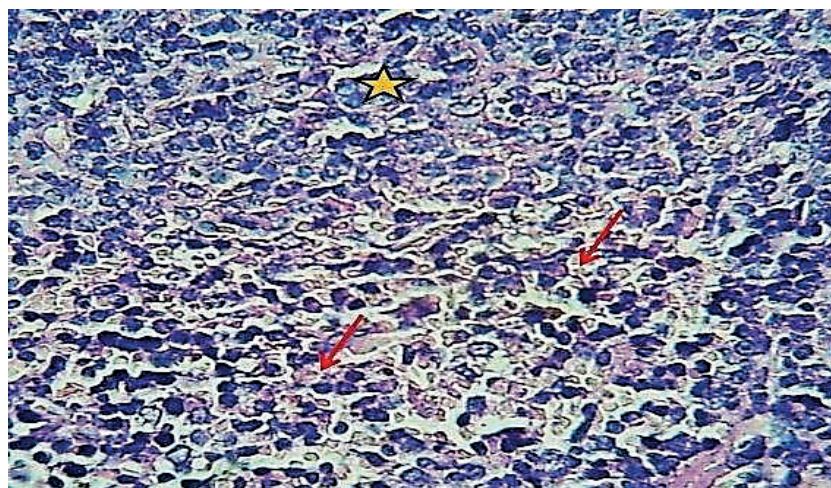


4c.





4d.



4e.

**Fig. 4. Section of spleen. 4a. – section of spleen (125 mg/kg of Sudafed) shows: moderate vascular and sinusoidal congestion (Red arrows) and with normal lymphoid follicles (Wp). H and E stain 100x; 4b. – section of spleen (125 mg/kg of Sudafed) shows: mild sinusoidal congestion (Red arrows) and little inflammatory infiltrate (yellow arrow), amyloid deposition (Asterisk) and megakaryocytes (Black arrow). H and E stain 400x; 4c. – section of spleen (62.52 mg/Kg of Sudafed) shows: mild sinusoidal congestion (Red arrows) and little inflammatory infiltrate (Black arrows). H and E stain 400x; 4d. – section of spleen (62.52 mg/kg of Sudafed) shows: mild sinusoidal congestion (Red arrows) and megakaryocytes (Asterisk). H and E stain 400x; 4e. – section of spleen (31.24 mg/kg of Sudafed) shows: preserved architecture with normal lymphoid follicles of white pulp (Asterisk) and mild sinusoidal congestion of red pulp (Red arrow). H and E stain 400x**

Pharmacotherapy is inevitably associated with the risk of drug-related complications; the most controversial is the effect of pseudoephedrine on body organs and its consequences. Some literature data suggested that oral sympathomimetic drugs may dangerously increase blood pressure, while others reassured that the danger is exaggerated [10, 12]. In general, the consequence of this drug on body organs and on spleen in certain, is not well established [11, 13]. First of all, and in terms of animals' behavior, the present study demonstrated that intraperitoneal PSE increased the activity and aggressive behavior as well as anorexia, in addition to some pathological changes in spleen of

mice. The study revealed some changes in spleen tissues especially at high concentration (500 mg/kg) of PSE. The findings after 24 hrs. of one intraperitoneal injection showed sever splenic hemorrhage and sinusoidal dilation with hyperplasia of lymphoid follicles. Our results are in the harmony with previous studies which recorded pathological changes of high doses of PSE on liver and kidneys of albino mice [11], and this boosts the opinion of toxic effect of PSE on body organs in general [14, 15, 16]. Other study showed that the potential complications of damaged spleen include the reduction of number of healthy red blood cells, platelets and white cells in bloodstream, leading to

more frequent infections, as well as anemia and increased bleeding are possible complications [17, 18]. Moreover, the possibility of rupture is much greater when spleen is enlarged. A ruptured spleen can cause life-threatening bleeding in belly [19, 20].

#### CONCLUSION

It is worth to be mentioned that to our knowledge there are no previous works dealing with the effect of PSE on spleen. Therefore, there are clear limitations to this study. We were unable to make further comparisons due to the scarcity of references or previous works in this aspect and this limited the interpretation of the results.

**Acknowledgment.** The article's authors would like to express their gratitude to everyone who helped them with this task.

#### Contributors:

Yasmin L. Alsaadi, Bassam K. Abdul Ameer, Ban Jasim Mohamad, Faiza Kathum Omra – investigation, resources, formal analysis, conceptualization, writing – original draft, writing – review & editing, visualization

**Funding.** This research received no external funding.

**Conflict of interests.** The authors declare no conflict of interest.

## REFERENCES

- Głowacka K, Anna WH. Pseudoephedrine-Benefits and Risks. *International Journal of Molecular Sciences*. 2021;22(10):5146. doi: <https://doi.org/10.3390/ijms22105146>
- Rahman Z, Aqueel MS, Korang-Yeboah M, Zidan AS, Chen J, Alayoubi AY, et al. Evaluation of commercially available meth-deterrent pseudoephedrine hydrochloride products. *Int J Pharm*. 2020 Feb 15;575:118909. doi: <https://doi.org/10.1016/j.ijpharm.2019.118909>
- Hussain L, Reddy V, Maani C. Physiology, Noradrenergic Synapse. In: *StatPearls* [Internet]. Treasure Island (FL): StatPearls Publishing; 2024 [cited 2024 Aug 15]. Available from: <https://www.ncbi.nlm.nih.gov/books/NBK540977/>
- Brandon P, Bob B, John C, Fran D, Gerry Mc. Efficiency of extraction and conversion of pseudoephedrine to methamphetamine from tamper-resistant and non-tamper-resistant formulations. *Journal of Pharmaceutical and Biomedical Analysis*. 2018;156:16-22. doi: <https://doi.org/10.1016/j.jpba.2018.04.016>
- Horowitz A, Frey D, Denault D. Sympathomimetics. In: *StatPearls* [Internet]. Treasure Island (FL): StatPearls Publishing; 2024 [cited 2024 Aug 15]. Available from: <https://www.ncbi.nlm.nih.gov/books/NBK546597/>
- Lowry J, Brown J. Significance of the imidazole receptors in toxicology. *Clinical toxicology*. 2014 Jun;52(5):454-69. doi: <https://doi.org/10.3109/15563650.2014.898770>
- National Center for Biotechnology Information. PubChem Compound Summary for CID 7028 [Internet]. Pseudoephedrine. 2024 [cited 2024 Aug 15]. Available from: <https://pubchem.ncbi.nlm.nih.gov/compound/Pseudoephedrine>
- Laccourreya O, Werner A, Giroud JP, Couloigner V, Bonfils P, Bondon-Guitton E. Benefits, limits and danger of ephedrine and pseudoephedrine as nasal decongestants. *European Annals of Otorhinolaryngology, Head and Neck Diseases*. 2015;132(1):31-4. doi: <https://doi.org/10.1016/j.anorl.2014.11.001>
- Beck KR, Thompson GR. Odermatt, Drug-induced endocrine blood pressure elevation. *Pharmacol Res*. 2020;154:104311. doi: <https://doi.org/10.1016/j.phrs.2019.104311>
- Ban J, Faeza A. The Effect of Pseudoephedrine (Sudafed) on Kinetic activity and histology of Livers and Kidneys in Albino Mice. *Research Journal of Pharmacy and Technology*. 2021;14(9):5015-8. doi: <https://doi.org/10.52711/0974-360X.2021.00874>
- protocols.io [Internet]. Available from: <https://www.protocols.io/view/hematoxylin-amp-eosin-protocol-for-leica-st5020-au-x54v9mozqg3e/v1>
- Pawan M, Amandeep S, Krishika S, Pragati J, Chaudhary M, Chinmayee M, Poorvi UP. Ephedrine and Pseudoephedrine: A Comprehensive Review of Their Pharmacology and Clinical Applications. *The JCHR*. 2024;14:1447-55.
- Ahmad S. Recent advances in Pharmacology and Toxicology of Phytopharmaceuticals. *Asian J Pharm Res*. 2017;7(4):222-4. doi: <https://doi.org/10.5958/2231-5691.2017.00034.X>
- Goud MC, Ghazanfar SM. Nimesulide – A Drug to be Banned completely. *Asian Journal of Pharmaceutical Research*. 2021;11(2):132-7. doi: <https://doi.org/10.52711/2231-5691.2021.00025>
- Kumaraswamy G, Gandla L, Swetha K, Suthakaran R, Ramesh Babu GA. Validated RP-HPLC Method for Simultaneous Estimation of Pseudoephedrine and Terfenadine in its Bulk and Pharmaceutical Dosage forms. *Asian J Pharm Tech*. 2014;4:(Iss 4):200-4.
- Sohn JS, Choi J-S. Development and evaluation of pseudoephedrine hydrochloride abuse-deterrent formulations using thermal modified rice starch. *International Journal of Biological Macromolecules*. 2021;182:1248-58. doi: <https://doi.org/10.1016/j.ijbiomac.2021.05.055>
- Chapman J, Goyal A, Azevedo AM. Splenomegaly. In: *StatPearls* [Internet]. Treasure Island (FL): StatPearls Publishing; 2024 [cited 2024 Aug 15]. Available from: <https://www.ncbi.nlm.nih.gov/books/NBK430907/>
- Vaseeha Banu TS, Awdesch JV, Ansari MS. Formulation and Evaluation of Transdermal Patches of Decongestant Drug. *Research Journal of Pharmaceutical Dosage Forms and Technology*. 2022;14(3):195-8. doi: <https://doi.org/10.52711/0975-4377.2022.00031>

19. Bitar Y. Separation and Assay of Three Anti-Cough Drugs Pseudoephedrine, Dextromethorphan and Chlorpheniramine in Pharmaceutical Forms by using single RP-HPLC Method. *Research J Pharm and Tech.* 2020;13(2):831-9. doi: <https://doi.org/10.5958/0974-360X.2020.00157.2>

20. Waseem M, Bjerke S. Splenic Injury. In: StatPearls [Internet]. Treasure Island (FL): StatPearls Publishing; 2024 [cited 2024 Aug 15]. Available from: <https://www.ncbi.nlm.nih.gov/books/NBK441993/>

Стаття надійшла до редакції 04.10.2024;  
затверджена до публікації 20.11.2024

