

11. Ho RC, Thiaghu C, Ong H, Lu Y, Ho CS, Tam WW, Zhang MW. A meta-analysis of serum and cerebrospinal fluid autoantibodies in neuropsychiatric systemic lupus erythematosus. *Autoimmun Rev.* 2016 Feb;15(2):124–138. doi: 10.1016/j.autrev.2015.10.003.
12. Monahan RC, Beart-van de Voorde LJJ, Steup-Beekman GM, Magro-Checa C, Huizinga TWJ et al. Neuropsychiatric symptoms in systemic lupus erythematosus: impact on quality of life. *Lupus.* 2017 Oct;26(12):1252–1259. doi: 10.1177/0961203317694262.
13. Sarwar S, Mohamed AS, Rogers S, Sarmast ST, Kataria S, Mohamed KH et al. Neuropsychiatric Systemic Lupus Erythematosus: A 2021 Update on Diagnosis, Management, and Current Challenges. *Cureus.* 2021 Sep 14;13(9): e17969. doi: 10.7759/cureus.17969.
14. Tan Z, Zhou Y, Li X, Wang G, Tao J, Wang L et al. Brain magnetic resonance imaging, cerebrospinal fluid, and autoantibody profile in 118 patients with neuropsychiatric lupus. *Clin Rheumatol.* 2018 Jan;37(1):227–233. doi: 10.1007/s10067-017-3891-3.
15. Zardi EM, Giorgi C, Zardi DM. Diagnostic approach to neuropsychiatric lupus erythematosus: what should we do? *Postgrad Med.* 2018 Aug;130(6):536–547. doi: 10.1080/00325481.2018.1492309.

Стаття надійшла 3.04.2023 р.

DOI 10.26724/2079-8334-2024-2-88-71-76

UDC 611.748.22.06-044.5-073.432.19:796.332.071.2

S.Yu. Karatieieva, O.M. Slobodian, I.M. Tsurkan, G.O. Kozlovskaya¹, V.K. Grodetsky
Bukovinian State Medical University, Chernivtsi
¹**Dnipro State Medical University, Dnipro**

COMPARATIVE MORPHOMETRIC CHARACTERISTICS OF THE RECTUS FEMORIS MUSCLE OF THE HIP ACCORDING TO THE DATA OF THE ULTRASOUND STUDY

e-mail: Karatsveta@gmail.com

The study was performed on 48 young men aged 16 to 18. The main group consists of 32 respondents, the control group – of 16 students. All respondents underwent a morphometric study using ultrasound diagnostics of the rectus femoris muscle. As a result of the comparison of the morphometric parameters of the bipinnate (rectus) femoris muscle according to the ultrasound examination, it was established that the volume in the upper third of the m. rectus femoris is greater in professional football players, compared to student football players, by 31.2 %, by 37.6 %, compared to the control group. Also, in football students the volume of m. rectus femoris in the upper third is by 9.4 % larger, compared to the control group. In the middle third, it is higher in professional football players by 39.3 % compared to student football players and by 35.4 % compared to the control group. In the lower third, it is higher in professional football players by 28.1 %, compared to student football players, and by 21.1 %, compared to the control group. There is practically no difference in the volume of the m. rectus femoris in the middle and lower third between football students and the control group.

Key words: muscles, anatomy, morphometry, ultrasound examination.

С.Ю. Каратєєва, О.М. Слободян, І.М. Цуркан, Г.О. Козловська, В.К. Гродецький **ПОРІВНЯЛЬНА МОРФОМЕТРИЧНА ХАРАКТЕРИСТИКА ДВОПЕРИСТОГО М'ЯЗА** **СТЕГНА ЗА ДАНИМИ УЛЬТРАЗВУКОВОГО ДОСЛІДЖЕННЯ**

Дослідження виконано на 48-ми юнаках, віком від 16 до 18 років. Основну групу становлять 32 респондента, контрольну – 16 студентів. Усім респондентам було проведено морфометричне дослідження за допомогою ультразвукової діагностики прямого м'яза стегна. В результаті проведеного порівняння морфометричних параметрів двоперистого (прямого) м'яза стегна за даними ультразвукового дослідження встановлено, що об'єм у верхній третині m. rectus femoris більший у професійних футболістів, порівняно з студентами-футболістами на 31,2 %, на 37,6 %, порівняно з контрольною групою. Також, у студентів-футболістів об'єм m. rectus femoris в верхній третині на 9,4 % більший, порівняно з контрольною групою. В середній третині більший у професійних футболістів на 39,3 %, порівняно з студентами-футболістами та на 35,4 %, порівняно з контрольною групою. В нижній третині більший у професійних футболістів на 28,1 %, порівняно з студентами-футболістами, та на 21,1 %, порівняно з контрольною групою. Різниця об'єму m. rectus femoris в середній та нижній третині між студентами-футболістами та контрольною групою практично немає.

Ключові слова: м'язи, анатомія, морфометрія, ультразвукове дослідження.

The work is a fragment of the research project "Regularities of sex-age structure and topographic-anatomical transformations of organs and structures of the body at the pre- and postnatal stages of ontogenesis. Peculiarities of perinatal anatomy and embryotopography", state registration No. 0120U101571.

Individual features of the athletes' body structure have a significant impact on the parameters of the coordination structure and are an objective cause of the variability of the movement system, which should be taken into account when correcting the individual model of the athletes' movement structure [1-5]. But in order to achieve certain success in sports, in addition to the study of biometric, anthropometric indices and the establishment of biomechanical technologies, morphometry is important for planning promising sports achievements. It should be noted that in the field of sports, information about muscle morphology is very valuable for diagnosis or further research after treatment or training [12].

Muscle structure and distribution play a central role in determining athletic performance, especially in sports involving speed and strength [7, 8, 9].

Ultrasound imaging is a tool commonly used to visualize soft tissue structures, permitting the quantification of muscle size and structure. These morphological variables are important determinants of muscle strength and tension force range [6, 14].

It is known that the muscles of the thigh include three groups of muscles: anterior, posterior and adductors. The most prominent of these muscle groups are the front muscles, which consist of the four muscles that make up the quadriceps. These muscles are the powerhouse of the body and provide short bursts of energy that allow players to sprint or maintain a steady run while playing. The development of these muscles makes players faster and also provides more power for kicking [7].

Therefore, ultrasound examination of the rectus femoris muscle in order to compare the morphometric parameters of football players for recommendations on sports selection is relevant and requires further study [10, 11, 13].

There are almost no works devoted to the study of the rectus femoris' es morphometric parameters using ultrasound.

The purpose of the study was to compare the volume of the rectus femoris muscle in order to determine the sports orientation and selection for professional football.

Materials and methods. The study was performed on 48 young men aged 16 to 18. The main group consisted of 32 respondents, of which group I included 16 players of the Ukrainian masters of sports football team "University", Chernivtsi, and group II – 16 students of the I–II courses of the Faculty of Physical Culture and Human Health at the Yuriy Fedkovich Chernivtsi National University. The III group was the control group, which consisted of 16 students of the I–II years of the college and dental faculties at the Bukovinian State Medical University.

Representatives of the main group were practically healthy (there was no congenital or chronic pathology in the anamnesis), among them were masters of sports of Ukraine, who systematically trained intensively and participated in the championships of Ukraine among higher educational institutions, under the leadership of the team coach. Training took place 3–4 times a week, for 1.5 hours on average, and football students who, in addition to the physical load included in the program of their specialty during the year, additionally (under the control of a coach, 3 times a week, for 1.5 hours on average) attended football sections.

The subjects of the control group were also practically healthy young men who were loaded with hours of physical education, according to the programs of their specialty, and additionally did not play sports. The mean body weight of the subjects is 78.50 ± 2.26 kg, height is 180.40 ± 2.36 cm.

All respondents underwent a morphometric examination with the help of ultrasound diagnostics of the rectus femoris muscle (musculus rectus femoris) using the VolusonTM E 10 device (Austria), in 2D linear sensor mode, on the basis of the Basismed medical center in Chernivtsi. The length, width and depth were set (in the upper third, in the middle, in the lower third) (Table 1).

The length of the rectus femoris muscle (m. réctus fémoris) was determined from the front lower iliac spine (straight head, cáput réctum) and from the area of the iliac bone above the acetabulum (rotated head, cáput refléxum), which pass into the common tendon. (Fig. 1). The width was determined between the edges in the widest part of the muscle. The depth was determined in the upper, middle and lower thirds of the muscle.

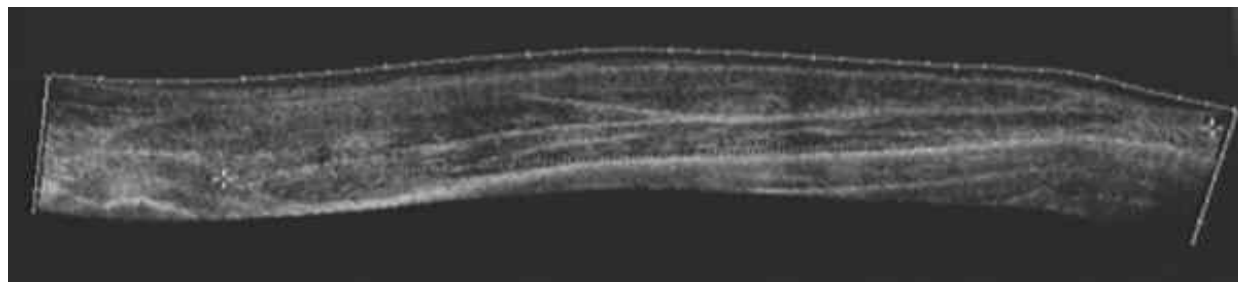


Fig. 1. Sagittal section of the hip of a young man D., 18 years old

The structure of m. rectus femoris was studied with the help of ultrasound (echogenicity, echo structure, blood flow and acoustic density).

Table 1 (the volume of m. rectus femoris in the upper, middle and lower thirds (mm^3), for each group display the mean (mean), limits of the 95 % confidence interval for the mean (lower, upper), root

mean square deviation (SD), and standard error (SE). A vertical height gauge was used to measure height. Body weight (weighing) was carried out on floor scales (electronic).

One-way ANOVA was used to identify significant differences in mean volume values between groups of respondents.

Table 1

Mean values of m. rectus femoris volume in the upper, middle and lower third (mm³)

| Mean values of m. rectus femoris volume in the upper third (mm ³) | | | | | |
|--|-----------|-----------|----------|-----------|-----------|
| Group | Mean | Lower | Upper | SD | SE |
| I | 2024593 | 1963363 | 2085823 | 169828.9 | 30021.80 |
| II | 1394435 | 1341191 | 1447680 | 142591.8 | 26033.58 |
| III | 1263426 | 1180254 | 1346599 | 222740.4 | 40666.65 |
| Mean values of m. rectus femoris volume in the middle third (mm ³) | | | | | |
| Group | Mean | Lower | Upper | SD | SE |
| I | 1630862.3 | 1505673.8 | 1756051 | 347226.49 | 61381.552 |
| II | 990854.8 | 978295.9 | 1003414 | 33633.35 | 6140.582 |
| III | 1053444.4 | 1014489.2 | 1092400 | 104323.85 | 19046.842 |
| Mean values of m. rectus femoris volume in the lower third (mm ³) | | | | | |
| Group | Mean | Lower | Upper | SD | SE |
| I | 808753.9 | 734451.5 | 883056.3 | 206087.29 | 36431.429 |
| II | 581491.6 | 567637.2 | 595346.1 | 37102.91 | 6774.033 |
| III | 638581.0 | 596316.7 | 680845.3 | 113185.94 | 20664.830 |

Results of the study and their discussion. It should be noted that in the field of sports, information about muscle morphology is very valuable for diagnosis or further research after treatment or training, as well as for the purpose of determining sports orientation and selection for professional football.

According to our ultrasound data of the rectus femoris muscle in professional football players and subjects of the control group, it was established that the echo structure of the m. rectus femoris in the respondents of all groups is not disturbed, the echogenicity is normal, the blood flow is normal, and the acoustic density is normal.

Thus, the results of our study show that the mean value of the volume of m. rectus femoris in the upper third for the first group is 2024593 mm³, the 95 % confidence interval for the mean is (1963363;




Fig. 2. The difference between the mean values of the assessment of the m. rectus femoris volume in the upper third

One-way analysis of variance showed that there is a statistically significant difference in the mean values of the assessment of the m. rectus femoris volume in the upper third between the groups (FWelch (2,57.56)=163.34, p<0.001). The value of $\omega^2=0.84$, 95% CI=(0.78; 1), shows that the volume of m. rectus femoris in the upper third has a strong influence on the groups of respondents (Fig. 1)

The scale of Discovering Statistics Using IBM SPSS Statistics was used for interpretation: ES < 0.01 – Very small, 0.01 ≤ ES < 0.06 – Small, 0.06 ≤ ES < 0.14 – Medium, ES ≥ 0.14 – Large.

As a result of the Games-Howell post hoc test, it was found that the mean value of the volume of m. rectus femoris in the upper third was significantly different between groups I and II ($p < 0.001$), I and III ($p < 0.001$), II and III ($p = 0.02$).

M. rectus femoris in the upper third significantly differed between groups I and II ($p < 0.001$), I and III ($p < 0.001$), II and III ($p = 0.02$).




Fig. 3. The difference in the mean values of the m. rectus femoris volume assessment in the middle third

As a result of the Games-Howell post hoc test, it was found that the mean value of the volume of m. rectus femoris in the middle third was significantly different between groups I and II ($p < 0.001$), I and III ($p < 0.001$).




Fig. 4. The difference between the mean values of the assessment of the volume of m. rectus femoris in the lower third

As a result of the Games-Howell post hoc test, it was found that the mean value of the volume of m. rectus femoris in the middle third was significantly different between groups I and II ($p < 0.001$), I and III ($p < 0.001$).

Thus, according to the results of the m. rectus femoris volume in the upper third, there is obviously a difference between professional football players and student football players, where a larger volume in the upper third is noted in professional football players, compared to student football players by 31.2 %, and also a large difference between professional football players and the control group – 37.6 %. There is also a difference between representatives of the II and III groups, where football students have a larger volume of m. rectus femoris in the upper third by 9.4 %, compared to the control group (students who do not play sports).

According to the results of the m. rectus femoris volume in the middle third, there is also a difference between professional football players and student football players, where a larger volume in the middle third is noted in professional football players by 39.3 %, compared to student football players, as well as a difference between professional football players and the control group is 35.4 %. There is practically no difference between II and III groups.

According to the results of the m. rectus femoris volume in the lower third, there is an obvious difference between professional football players and student football players, where a larger volume in the lower third is noted in professional football players by 28.1 %, compared to student football players, and

One-way analysis of variance showed that there was a difference in the mean values of m. rectus femoris volume assessment in the middle third between the two groups ($F_{\text{Welch}}(2,44.16) = 56.91$, $p = 5.98e-13$). The value of $\omega^2_p = 0.70$, $CI = (0.57; 1.00)$, shows that the volume of m. rectus femoris in the middle third also has an impact on the groups of respondents (Fig. 2).

One-way analysis of variance showed that there is a difference in the mean values of m. rectus femoris volume assessment in the lower third between the two groups ($F_{\text{Welch}}(2,45.07) = 21.07$, $p = 3.42e-07$). The value of $\omega^2_p = 0.46$, $CI = (0.27; 1.00)$, shows that the volume of m. rectus femoris in the lower third also has an effect on two groups of respondents (Fig. 3).

also the difference between professional football players and the control group is 21.1 %. There is practically no difference between II and III groups.

Thus, it was established that professional football players have the largest volume of m. rectus femoris, compared to student football players and control groups, and the smallest volume of the studied control group.

After performing a search for scientific works in the field of morphometric studies of the rectus femoris muscle in football players, with the help of ultrasound research, it was concluded that there were very few scientific works in this direction. Therefore, given that some scientists have developed a way to morphometrically study muscles using ultrasound, namely Guido Weide (2017), who developed a way to perform 3D morphological ultrasound analysis of muscles.

In his opinion, it is the ultrasound image that permits to quantify the size of the muscles, the length of the bundles and the angle of withdrawal. These morphological variables are important determinants of muscle strength and the range of force of tension. The author described an approach to determining the volume and length of bundles m. vastus lateralis and m. gastrocnemius medialis. He also believes that ultrasound provides a rapid and cost-effective approach for quantifying the 3D morphology of skeletal muscle, because in sports, information about muscle morphometry is very valuable for diagnosis and prospective planning after treatment or training. As a result, the method provides a visualization tool that can be used for a variety of purposes and settings in sports. The use of 3DUS to monitor athletes at risk of muscle loss is important and potentially permits adjustments in exercise. Another possible application of 3DUS is to monitor the morphological adaptation of muscles in response to training and/or injury [15].

V.V. Gayovych (2014) studied, with the help of ultrastructural studies, the features of denervation processes in the muscles of the limbs, as well as the reason for greater tolerance of the muscles of the limb to denervation in the experiment. Morphometric analysis was performed on electrograms by studying morphometric indices (cross-sectional area of muscle fibers as an index of their swelling and dystrophy; number of muscle fiber nuclei (myonuclei); the area of muscle fiber nuclei as a marker of hypotrophic changes; the cross-sectional area of the structural elements of the microcirculatory bed as an index of changes in the regional microcirculation of satellite cells, destruction of sarcomeres of contractile myofibrils and dilation of hemocapillaries and muscle venules). As a result of the study, denervation processes were accompanied by replacement of denervated muscle by stromal elements [1].

Summarizing the results of similar studies, A. J. McComas concluded that even high-intensity endurance training does not significantly affect the ratio of fiber types. Hence, it is reasonable to assume that the effect of training on the change in muscle composition is possible only within 5–6 %.

R.V. Klymovytskyi (2017) believes that when the composition of muscle fibers does not match the nature of the work performed (the chosen sports specialization), the growth of sports skills stops. Such athletes, as a rule, are eliminated in the process of multi-year selection, because the force of isolated skeletal muscle contraction depends on its length, and a small stretch of the muscle leads to the fact that the force it develops is increased compared to the force developed by an unstretched muscle, due to the summation of the passive tension of the elastic components of the muscle and the active contraction. And it is a gross mistake to believe that any stretching of a muscle will increase the strength of its contraction [2].

Therefore, there are almost no works devoted to morphometric studies of the rectus femoris muscle using ultrasound for the purpose of recommendations regarding sports eligibility and selection.

Therefore, in our opinion, during sports selection, it is recommended to also take into account the morphometric characteristics of the rectus femoris muscle, using ultrasound, since the load on it during the game of football is quite large, and the structural and morphometric characteristics of the rectus femoris muscle steady running during the game as well depends on, which makes players faster and also gives more power to kick.

In summary, it can be concluded that the ultrasound examination of the m. rectus femoris to determine the volume in the upper, middle and lower third has a practical value for the recommendation for the purpose of determining the sports orientation and selection for professional football.

Conclusions

1. According to the research results, the volume in the upper third of the m. rectus femoris is greater in professional football players, compared to student football players by 31.2 %, by 37.6 %. compared to the control group.

2. According to the research results, the volume of m. rectus femoris in the upper third of football students is by 9.4 % larger, compared to the control group.

3. According to the results, the volume of m. rectus femoris in the middle third is greater in professional football players by 39.3 %, compared to student football players and by 35.4 %, compared to the control group.

4. According to the research results, the volume of m. rectus femoris in the lower third is greater in professional football players by 28.1 %, compared to student football players, by 21.1 %, compared to the control group.

5. There is practically no difference in the volume of m. rectus femoris in the middle and lower third between football students and the control group.

6. Ultrasound examination of the m. rectus femoris to determine the volume in the upper, middle and lower third has a practical value in relation to the recommendation for the purpose of determining the sports orientation and selection for professional football.

References

1. Haiovych V.V. Osoblyvosti strukturnykh zmin skeletnykh miaziv kintsivok pry tryvalii denervatsii v eksperymenti. Visnyk ortopedii, travmatolohii ta protezuvannia. 2014; 4: 42–46. [in Ukrainian]
2. Klymovytskiy R.V. Kliniko-biomekhanichne obgruntuvannia ta pobudovani modeli roboty myshi, shcho zabezpechuiut horyzontalne rivnovahu taza Travma. 2017;18 (5): 13–19. doi:10.22141/1608-1706.5.18.2017.114115 [in Ukrainian]
3. Ezeiza J, Tam N, Torres-Unda J, Granados C, Santos-Concejero J. Anthropometric characteristics of top-class Olympic race walkers. Journal of Sports Medicine and Physical Fitness. 2019; 59(3): 429–433. <https://doi.org/10.23736/S0022-4707.18.08363-9>
4. Gardasevic J, Bjelica D, Vasiljevic I, Corluca M, Arifi F, Sermaxhaj S. Morphological Characteristics and Body Composition of the Winners of the Soccer Cup of Bosnia and Herzegovina and Kosovo. Sport Mont 2020;18 (1): 103–105. doi: 10.26773/smj.200219
5. Gusic M, Popovic S, Masanovic B, Radakovic M. Sport-specific morphology profile: differences in anthropometric characteristics among elite soccer and handball players. Sport Mont 2017; 15 (1): 3–6. http://www.sportmont.uceg.ac.me/clanci/SM_februar_2017_Gusic.pdf
6. Hyka A, Bicoku E, Mysliu A, Cuka A. The Association of Sprint Performance with Anthropometric Parameters in Youth Soccer Players. Sport Mont. 2017; 15 (1): 31–33. http://www.sportmont.uceg.ac.me/clanci/SM_februar_2017_Hyka.pdf
7. Karatieieva S, Slobodian O, Lukashiv T, Honchar H, Komar V, Kozlovskaya S. The determination of distal hip circumference in universities students depending on the sport type. Health, sport, rehabilitation. 2022; 8(3): 27–37 doi: <https://doi.org/10.34142/HSR.2022.08.03.02>
8. Kendall K, Fukada D, Hyde P, Smith-Ryan A, Moon J, Stout J. Estimating fat-free mass in elite-level male rowers: a four-compartment model validation of laboratory and field methods. Journal of Sports Science. 2017; 35(7): 624–633. <https://doi.org/10.1080/02640414.2016.1183802>
9. Kerr A, Slater G. Impact of food and fluid intake on technical and biological measurement error in body composition assessment methods in athletes. 2017; British Journal of Nutrition. 117; 591–601. <https://doi.org/10.1017/S0007114517000551>
10. Masanovic B, Bavcevic T, Bavcevic I. Comparative Study of Anthropometric Measurement and Body Composition between Junior Soccer and Volleyball Players from the Serbian National League. Sport Mont 2019; 17 (1): 9–14. doi: 10.26773/smj.190202
11. Pavlović R, Mihajlović I, Radulović N, Nikolić S. Anthropometric parameters of elite male runners sprint: are body height and body weight good predictors of results. Health, sport, rehabilitation, 2022; 8(3): 64–74 doi: <https://doi.org/10.34142/HSR.2022.08.03.05>
12. Thomas D, Erdman K, Burke L. American College of Sports Medicine joint position statement. Nutrition and athletic performance. Medicine and Science in Sports and Exercise. 2016; 48(3); 543–568. <https://doi.org/10.1249/MSS.0000000000000852>
13. Vujkov S, Casals C, Krneta Z, Drid P. Ultra short-term heart rate recovery after maximal exercise in two different body positions in elite male judokas compared to students of the sport faculty. Sport Mont. 2016; 14 (1): 7–11. http://www.sportmont.uceg.ac.me/clanci/SM_feb_2016_Vujkov.pdf
14. Wakahara T, Ema R, Miyamoto N, Kawakami Y. Inter- and intramuscular differences in training-induced hypertrophy of the quadriceps femoris: association with muscle activation during the first training session. Clin. Physiol. Funct. Imaging. 2015; 37(4):405–412. doi:10.1111/cpf.12318
15. Weide G, Zwaard S, Huijting A, Jaspers T. 3D Ultrasound Imaging: Fast and Cost-effective Morphometry of Musculoskeletal Tissue. J Vis Exp. 2017. Issue 129. P. 55943. doi:10.3791/55943

Стаття надійшла 9.03.2023 р.