



# Wiadomości Lekarskie

Czasopismo Polskiego Towarzystwa Lekarskiego



Pamięci  
dra Władysława  
Biegańskiego

TOM LXXII, 2019, Nr 5 cz II, maj

Rok założenia 1928

---

Wiadomości Lekarskie is abstracted and indexed in: PubMed/Medline, EBSCO, SCOPUS, Index Copernicus, Polish Medical Library (GBL), Polish Ministry of Science and Higher Education.

Copyright: © ALUNA Publishing.

Articles published on-line and available in open access are published under Creative Commons Attribution-Non Commercial-No Derivatives 4.0 International (CC BY-NC-ND 4.0) allowing to download articles and share them with others as long as they credit the authors and the publisher, but without permission to change them in any way or use them commercially.

## **Zasady prenumeraty miesięcznika Wiadomości Lekarskie na rok 2019**

**Zamówienia na prenumeratę przyjmuje Wydawnictwo Aluna:**

**- e-mailem: [prenumerata@wydawnictwo-aluna.pl](mailto:prenumerata@wydawnictwo-aluna.pl)  
- listownie na adres:**

**Wydawnictwo Aluna  
ul. Z.M. Przesmyckiego 29, 05-510 Konstancin-Jeziorna**

**Prosimy o dokonywanie wpłat na numer rachunku Wydawnictwa:  
Credit Agricole Bank Polska S. A.: 82 1940 1076 3010 7407 0000 0000**

Cena prenumeraty dwunastu kolejnych numerów: 240 zł/rok (w tym 5% VAT)

Cena prenumeraty zagranicznej: 120 euro/rok.  
Cena pojedynczego numeru – 30 zł (w tym 5% VAT) + koszt przesyłki.  
Przed dokonaniem wpłaty prosimy o złożenie zamówienia.

**In the "Wiadomości Lekarskie" Journal (issue No 4, volume 72, 2019)  
the article of Nadiia V. Shulzhenko entitled "LEGAL BASES FOR IMPROVING  
LEGISLATION ON THE TRANSPLANTATION OF HUMAN  
ANATOMICAL MATERIAL" was published, which after releasing the paper  
version was withdrawn from the electronic version of the Journal  
(pdf, [www.wiadomoscilekarskie.pl](http://www.wiadomoscilekarskie.pl)) due to the suspicion of plagiarism.**



# Wiadomości Lekarskie

**Editor in-Chief:**

Prof. Władysław Pierzchała

**Deputy Editor in-Chief:**

Prof. Aleksander Sieroń

**Statistical Editor:**

Dr Lesia Rudenko

**Polskie Towarzystwo Lekarskie:**

Prof. Waldemar Kostewicz – President PTL

Prof. Jerzy Woy-Wojciechowski – Honorary President PTL

Prof. Tadeusz Petelenz

---

**International Editorial Board – in-Chief:**

Marek Rudnicki

Chicago, USA

**International Editorial Board – Members:**

Kris Bankiewicz	San Francisco, USA	George Krol	New York, USA
Christopher Bara	Hannover, Germany	Krzysztof Łabuzek	Katowice, Poland
Krzysztof Bielecki	Warsaw, Poland	Henryk Majchrzak	Katowice, Poland
Zana Bumbuliene	Vilnius, Lithuania	Ewa Małecka-Tendera	Katowice, Poland
Ryszarda Chazan	Warsaw, Poland	Stella Nowicki	Memphis, USA
Stanislav Czudek	Ostrava, Czech Republic	Alfred Patyk	Gottingen, Germany
Jacek Dubiel	Cracow, Poland	Palmira Petrova	Yakutsk, Russia
Zbigniew Gasior	Katowice, Poland	Krystyna Pierzchała	Katowice, Poland
Andrzej Gładysz	Wroclaw, Poland	Tadeusz Płusa	Warsaw, Poland
Nataliya Gutorova	Kharkiv, Ukraine	Waldemar Priebe	Houston, USA
Marek Hartleb	Katowice, Poland	Maria Siemionow	Chicago, USA
Roman Jaeschke	Hamilton, Canada	Vladyslav Smiiianov	Sumy, Ukraine
Andrzej Jakubowiak	Chicago, USA	Tomasz Szczepański	Katowice, Poland
Oleksandr Katrushov	Poltava, Ukraine	Andrzej Witek	Katowice, Poland
Peter Konturek	Saalfeld, Germany	Zbigniew Wszolek	Jacksonville, USA
Jerzy Korewicki	Warsaw, Poland	Vyacheslav Zhdan	Poltava, Ukraine
Jan Kotarski	Lublin, Poland	Jan Zejda	Katowice, Poland

---

**Managing Editor:**

Agnieszka Rosa

amarosa@wp.pl

**Graphic design / production:**

Grzegorz Sztank

www.red-studio.eu

**International Editor:**

Lesia Rudenko

l.rudenko@wydawnictwo-aluna.pl

**Publisher:**

ALUNA Publishing

ul. Przesmyckiego 29, 05-510 Konstancin – Jeziorna

www.aluna.waw.pl www.wiadomoscilekarskie.pl

www.medlist.org

**Distribution and Subscriptions:**

Bartosz Guterman prenumerata@wydawnictwo-aluna.pl

PRACA ORYGINALNA  
ORIGINAL ARTICLE

## CHANGES IN THE FUNCTIONAL CONDITION OF THE MASTICATORY MUSCLES WITH INCREASED TEETH ABRASION

Svetlana A. Pavlenko<sup>1</sup>, Elena V. Pavlenkova<sup>1</sup>, Iryna M. Tkachenko<sup>1</sup>, Alla I. Sidorova<sup>1</sup>, Yaroslav Y. Vodoriz<sup>1</sup>,  
Andriy V. Samoilenko<sup>2</sup>

<sup>1</sup>UKRAINIAN MEDICAL STOMATOLOGICAL ACADEMY, POLTAVA, UKRAINE

<sup>2</sup>STATE INSTITUTION "DNIPROPETROVSK MEDICAL ACADEMY OF THE MINISTRY OF HEALTH OF UKRAINE", DNIPRO, UKRAINE

### ABSTRACT

**Introduction:** The term "pathological abrasion" (increased abrasion) can be described as a loss of tooth hard tissue on the occlusal, oral, vestibular surfaces of teeth or in the occlusal area. Treatment of increased abrasion of teeth is a difficult task for the practical work of a dentist. The choice of the optimal treatment plan provides the greatest likelihood of long-term success and minimal probability of complication appearance.

**The aim** of our work was to study the functional activity of the masticatory muscles in the pathogenesis of the development of increased abrasion of tooth hard tissues.

**Materials and methods:** In order to achieve the goal of the study, an examination of patients aged between 19 and 69 years old was carried out in order to identify the number of persons with increased abrasion of teeth. During the examination of all patients one control and one researched group were formed. The patients of the control group (30 patients aged from 18 to 60 years) which had intact dental rows with any signs of increased tooth wear. The investigated group consisted of 25 patients, aged from 18 to 60 years. Depending on the complex treatment, the patients of the second group were divided into two subgroups. Subgroup 2A - (10 patients) with increased abrasion of tooth hard tissues with planned complex treatment of the disease without additional use of mouthguards after the end of treatment. For the patients from the 2B subgroup (15 people with increased abrasion of tooth hard tissues) a mouthguard was prescribed after the end of the complex treatment.

In order to study some peculiarities of the muscular activity of the maxillofacial region an electromyogram was taken from all participants before treatment and repeated in a six- and twelve-months term.

**Results and conclusions:** In our opinion, all manifestations of increased tooth abrasion are associated with changes in the muscular system, the motor apparatus and the nervous activity of the body. Regarding to this, the study of the propria muscular system and the related bone system can justify the usage of one or another prevention or treatment of the pathology. Based on the results of our research, we can conclude that the study of the functional state of the muscle complex is a fairly reliable prognostic sign in the study of such a disease as an increased tooth abrasion.

**KEY WORDS:** Increased tooth abrasion, electromyography, hard tooth tissues, masticatory muscles

Wiad Lek 2019, 72, 5 cz. II, 1002-1006

### INTRODUCTION

Pathological abrasion (increased abrasion) has always been described as a state of pronounced loss of tooth hard dental tissues among people that consumed raw, coarse food.

As civilization developed, food products began to undergo thermal and mechanical processing which led to a decrease in the prevalence of dental abrasion, but not to the disappearance of the pronounced loss of tooth hard tissues. Currently, the possible reasons of premature tooth abrasion are being actively discussed.

In the pathogenesis of increased tooth abrasion, the following factors occur:

- exogenous: increased occlusal overload; occupational hazards and dietary habits of patients; irrational prosthetics of teeth (without taking into the account coefficients of friction of the artificial material with tooth enamel and abrasiveness of the material itself);
- endogenous: metabolic disorders, endocrinopathy, bruxism, diseases of the gastrointestinal system.

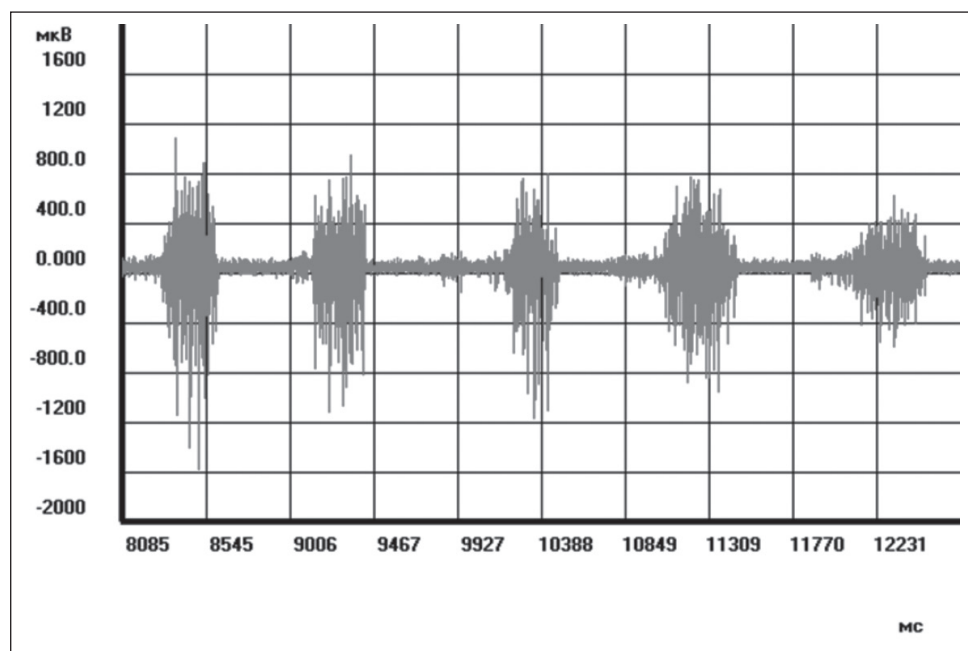
The main components that determine the increased abrasion of tooth hard tissues include: mechanical effect of occlusal load and resistance to wear of hard dental tissues. The mechanical effect of the occlusal load depends on the magnitude of the mastication force (pressure), the mechanism of wear of tooth hard tissues and the coefficient of friction.

### THE AIM

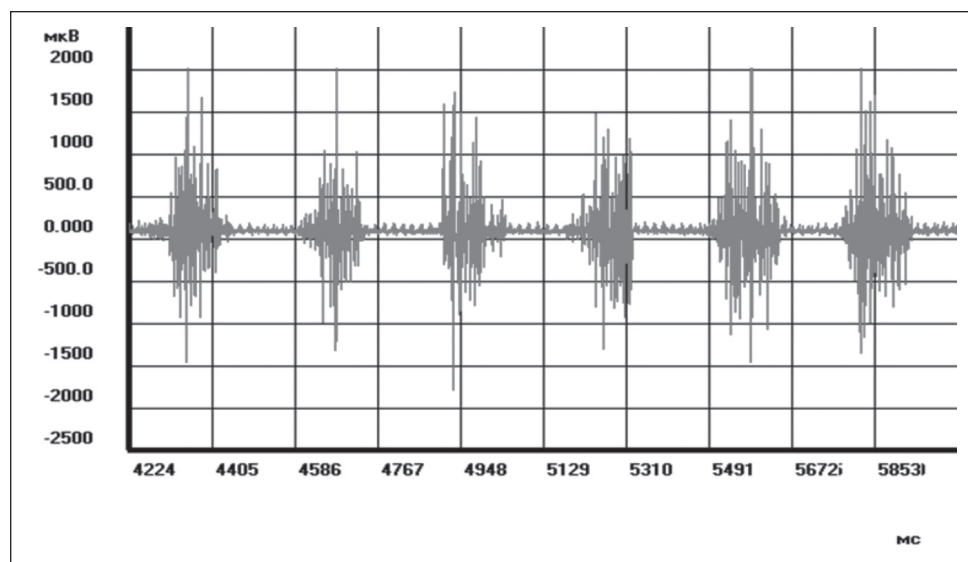
Based on the information mentioned above, the purpose of our work was to study the functional activity of the masticatory muscles in the pathogenesis of the development of increased abrasion of tooth hard tissues.

### MATERIALS AND METHODS

In order to solve the tasks, we conducted a clinical examination of patients aged from 19 to 69 years old, who were



**Fig. 1.** Fragment of the electromyogram of the right proper chewing muscle. P-ko, 29 years old.



**Fig. 2.** Fragment of the electromyogram of the left chewing muscle itself. F-va, 23 years

divided according to the age principle according to A. Moystrakh: patients up to 20 years old, 20-29 years old, 30-39 years old, 40-49 years old, 50-59 years and over 60 years.

Also, measurements of the sizes of the teeth of the upper and lower jaws were made in order to establish changes in the sizes of teeth in the age aspect, with various types of bite and with increased abrasion of teeth. Those measurements will determine the optimal average height of the coronal part of teeth to confirm the diagnosis of increased abrasion or prerequisites for its appearance.

In addition to the odontometric parameters, we studied the shape of crowns and cutting edges of upper incisors, canines, premolars and molars in order to establish erasure planes in the area of the chewing (cutting) surface and in the area of the contact surface of the equator. During the examination of all patients two groups were selected. The control group and the investigated one. In both groups,

we examined both male and female patients, who were equally divided into groups. It should be noted that majority of male patients was between the ages of 40 and 49, which accounted for 20% of the total number of patients in groups. Female patients were more in the age group of 20-29 years, which also accounted for 20% of the total number of patients in the groups.

The patients of the control group (30 patients aged from 18 to 60 years) had intact dental arches with no visible signs of increased tooth wear.

The researched group consisted of 25 patients, aged from 18 to 60 years. Depending on the complex treatment, the patients of the second group were divided into two subgroups. Subgroup 2A - (10 patients) with increased abrasion of tooth hard tissues with planned complex treatment [1,2] of the disease without additional use of mouthguards after the end of treatment. For the patients

**Table I.** The electromyogram parameters of patients in the control group (n = 30)

Masseter muscles	Parameters (M±m)			
	activity (ms.)	rest phase (ms.)	“K” index	Amplitude (mkV)
left	148,06±4,95	152,37±4,71	0,98±0,03	207,58±3,38
right	135,98±3,59	155,02±6,06	0,91±0,06	288,41±22,67

**Table II.** Electromyogram parameters of patients of the researched group (n = 25) before treatment

Subgroup	Masseter muscle	Parameters (M±m)			
		activity (ms.)	Rest phase (ms.)	«K» index	amplitude (mkV)
2-A (n=10)	left	226,69 ±35,39	300,57 ±30,93	0,64 ±0,063	284,67 ±34,21
	right	313,42 ±97,96	307,96 ±49,47	0,74 ±0,060	405,55 ±27,36
2-B (n=15)	left	305,51 ±14,39	354,35 ±14,75	0,81 ±0,035	482,23 ±50,62
	right	220,17 ±19,43	226,45 ±20,84	0,91 ±0,050	500,36 ±37,83

from the 2B subgroup (15 people with increased abrasion of tooth hard tissues) a mouthguard was prescribed after the end of the complex treatment.

For abrasion form verification the classification by Moldovanov A.G. (1992) [3] was used. For a more precise diagnosis the form of abrasion, its distribution and type (with or without decrease in interalveolar height), as well as the presence of hyperesthesia were also determined [4]. The type of occlusion according to Grigorieva [5] was also registered for each participant. Also, an attention was paid to the presence of defects in separate teeth, dentofacial deformities, rationality of prosthetics measures applied. In order to study some peculiarities of the muscular activity of the maxillofacial region an electromyogram was taken from all participants before treatment and repeated in a six- and twelve-months term.

Electromyographic studies are based on the study of action potentials of muscle fibers, which function as part of mobile units, since they are a functional unit of the activity of the neuromuscular apparatus [6]. For the myographic registration a four-channel myograph M-440, a computer and a printer were used. Recording was performed in the following mode:

- calibration signal
- calmness
- compression of jaws
- arbitrary chewing
- swallowing.

Patients of both the groups were examined following this protocol. All electromyograms are analyzed by qualitative and quantitative indicators [6, 7]. Assessing the quality indicators, we considered the presence or absence of activity at rest, the nature of the excitation force during maximal occlusal compression, sequential nature of chewing, the uniformity of alternation of periods of bioelectric activity

and rest. Quantitative data analyzed with Student-Fisher's statistical method using a computer program that included the definition of parameters:

- amplitude of oscillations (minimum and maximum,  $\mu V$ ) characterizing the excitation force and the number of motor units involved in muscle contraction;
- activity time, as an indicator of concentration in time of the excitation process, rest period as an indicator of the concentration of inhibitory processes and one dynamic cycle (ms);
- coefficient “K” as an indicator of the ratio of the processes of excitation and inhibition in each “activity” - “rest” dynamic cycle [8,9].

In order to compare the obtained data, indicators of the control group were used, which in the majority correspond to the normal indicators, according to the conducted studies [8].

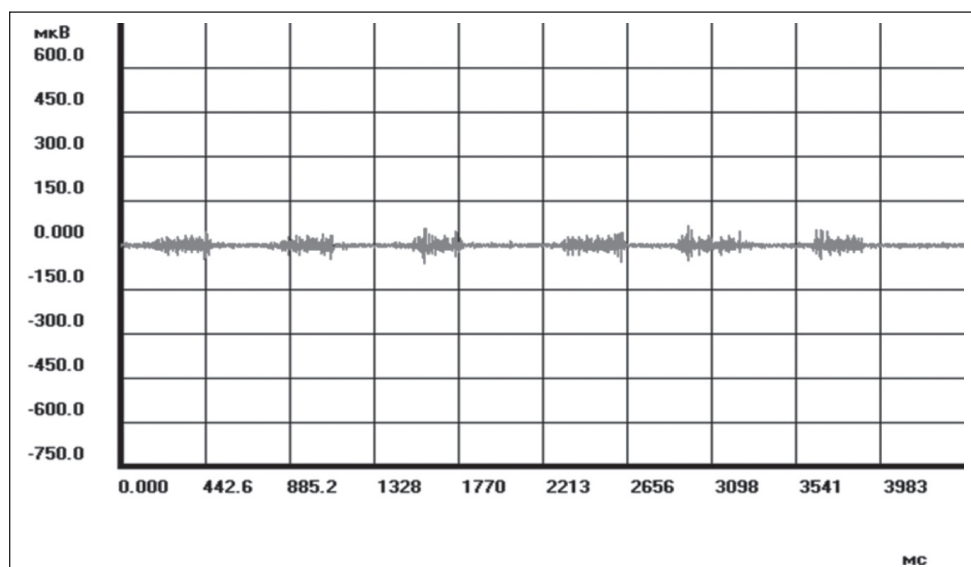
All work was conducted in accordance with the Declaration of Helsinki (1964) and was approved by the Ethical Committee of the academy.

## RESULTS

The quantitative and qualitative characteristics of bioelectric activity of the masticatory muscles of patients from the control group was studied. The state of relative physiological rest on the electromyogram is indicated by an isometric line (Fig. 1.).

For the electromyographic examination of patients from the control group a functional test “free chewing” was applied. The results show the alternation of volleys of activity with periods of relative bioelectric rest (Fig. 2).

Analyzing the digital data of electromyograms of patients from the control group, we noticed that the activity time and rest time of both the right and left masticatory muscles did not differ much.



**Fig. 3.** Fragment of the electromyogram of the chewing muscle of patient N. (47 years old) of the study group before treatment.

**Table III.** The electromyogram parameters of patients of the researched group (n = 25) one year after treatment

Subgroup	Masseter muscle	Parameters (M±m)			
		activity (ms.)	Rest phase (ms.)	«K» index	amplitude(mkV)
2 - A (n=10)	left	211,13 ±25,78	224,36 ±15,35	0,84 ±0,014	356,95 ±26,21
	right	254,89 ±58,68	221,86 ±28,81	0,84 ±0,03	417,44 ±26,99
2 - B (n=15)	left	290,69 ±14,98	246,25 ±10,89	0,88 ±0,022	540,65 ±35,20
	right	171,18 ±11,64	211,39 ±16,80	0,91 ±0,03	469,16 ±31,44

Notable that the activity coefficient “K” for the left and right masticatory muscles is different and is therefore  $0.98 \pm 0.03$  i  $0.91 \pm 0.06$ , but this difference is not significant and indicates the absence of functional asymmetry.

There is a significant difference in the amplitude of the left and right masticatory muscles. This may indicate a more active movement of the right proper masseter muscle in comparison with the left one.

It can be concluded that during chewing the muscles are capable of instantaneous activation and an equally rapid transition to a state of rest. From the data obtained it is clear that the muscles of both sides take different parts in the act of mastication and differ in functional asymmetry.

Prior to treatment, the data of electromyographic studies in patients of the second group was slightly different from those in the control group. A difference in the indices was also observed in patients and in subgroups of the researched group. In our opinion, this fact indicates a decrease in mastication efficiency, which is associated with the pathology of tooth hard tissues and a decrease of occlusion height in the case of increased abrasion. (Fig.3).

The results of the analysis of electromyograms of the researched group are presented in Table II.

From the data obtained in patients of the researched group, there is a difference between the indicators of the right and left side.

It should be noted that the coefficient of mastication activity in the subgroup 2A is significantly lower in the left muscle than in the right ( $0.64 \pm 0.063$  and  $0.74 \pm 0.060$  respectively), while in subgroup 2B the left and right muscles are higher, and equal to  $0.81 \pm 0.035$ ;  $0.91 \pm 0.050$  respectively. This suggests that before treatment the amplitude of the electromyogram of the right masseter muscle is larger, which means that it has performed chewing movements more actively.

A characteristic indicator of the masticatory function recovery is the activity coefficient of the masticatory muscles, which indicates changes in the activity time and rest time of the masticatory muscles when performing their functions. These changes can be traced in patients of the researched group one year after the treatment (table III).

The “K” coefficient in the researched group is gradually approaching the normal results ( $0.91 \pm 0.06$  and  $0.98 \pm 0.03$ ), which indicates an improvement in the adaptation of the patients of this group to therapeutic measures after the treatment.

In our opinion all manifestations of increased abrasion of teeth are associated with changes in the system of muscles, the motor apparatus and the nervous activity of the body. Regarding to this, the study of the directly muscular system and the related bone system can justify the use of one or another plan for the prevention and treatment of pathology, which is being studied.

## CONCLUSIONS

Based on our observations, we can conclude that the study of the functional state of the muscle complex is a fairly reliable prognostic sign in the study of diseases such as increased abrasion of teeth.

## REFERENCES

1. Tkachenko I, Kovalenko V, Skrypnikov P, Vodorig Y. Reasoning of the adhesive system for treatment of patients with increased tooth wear. *Wiadomości Lek.* 2018; 71 (6): 1129-34. Available from: <https://www.ncbi.nlm.nih.gov/pubmed/30267488>
2. Vodorig Y.Y. Fizychni vlastyvoli restavratsiynykh materialiv pry riznyi hlybyni preparuvannya tverdykh tkanyn zubiv [Physical properties of restorative materials at different depth of preparation of tooth hard tissues]. *News of problems in biology and medicine.* 2018; 4 (1). 186–188.
3. Moldovanov A.G. Fiziologiya i patologiya stiraniya tverdykh tkaney zubov. [Physiology and pathology of erasing hard dental tissues]. Simferopol. Tavriya; 1992; 185pp. (Ru).
4. Mezhdunarodnaya klassifikatsiya stomatologicheskikh bolezney na osnove MKB 10 [The international classification of dental diseases based on ICD 10]. VOZ. Geneva. 1997; 81 pp. (Ru)
5. Byikov V.L. Gistologiya i embriologiya organov polosti rta cheloveka. [Histology and embryology of human oral organs] SPb.1998; 248pp. (Ru).
6. Tkachenko I. Doslidzhennya funktsionalnoho stanu zhuval'nykh myaziv u normi elektromiografichnym metodom. [Research of the functional state of masticatory muscles in normal electromyographic method] *Ukrainian Dental Almanac.* 2012; 55-7. (Ua).
7. Georgiev V.I. Elektromiograficheskoe izuchenie funktsii zhevatelnykh myishch cheloveka pri intaktnom ortognaticheskom prikuse: [Electromyographic study of the function of the chewing muscles of a person with an intact orthognathic bite]. K.1969; p.19.(Ru).
8. Lebedenko I.Y. Funktsionalnyie i apparaturnyie metody issledovaniya v ortopedicheskoy stomatologii [Functional and instrumental methods of research in orthopedic dentistry]. MIA. 2002; 125pp. (Ru).
9. Malyuchenko M.M. Reografichil ta elektromiografichni pokazniki pri ortopedichnomu likuvanni patologichnoyi stertosti zubiv u osib starshih vikovih grup [Rheographic and electromyographic indices during orthopedic treatment of pathological dental rubbing of persons of older age groups] *Ukrainian dental almanach.* 2001; 3(4): 36-38. (Ua).

*This investigation is a fragment of the research of the Ukrainian stomatological academy "Morpho functional characteristics of oral cavity tissues and their impact on therapeutic measures and the choice of treatment materials. Registration number 01145U001112. No external funding was received during for this investigation.*

### Authors' contributions:

*According to the order of the Authorship*

### Conflict of interest:

*The Authors declare no conflict of interest*

---

## CORRESPONDING AUTHOR

**Elena V. Pavlenkova**

Ukrainian Medical Stomatological Academy  
Shevchenko 23 str., 36011 Poltava, Ukraine  
e-mail: pavlenkovaev@ukr.net

**Received:** 08.03.2019

**Accepted:** 29.04.2019