



Pediatric neuroinfection caused by *Borrelia burgdorferi* and *Varicella-zoster* virus: A case report

Olha Shvaratska¹✉, Victor Mavrutenkov², Tatiana Mavrutenkova³

¹MD, PhD, Associate Professor, Department of Pediatrics 3 and Neonatology, State Establishment "Dnipropetrovsk Medical Academy of Health Ministry of Ukraine", Dnipro, Ukraine;

²DM, Professor, Department of Infectious Diseases, State Establishment "Dnipropetrovsk Medical Academy of Health Ministry of Ukraine", Dnipro, Ukraine;

³PhD, Department of PCR Diagnostics, Diagnostic Center of Medical Academy, Dnipro, Ukraine

✉ Corresponding author

Associate Professor, Department of Pediatrics 3 and Neonatology, State Establishment "Dnipropetrovsk Medical Academy of Health Ministry of Ukraine", Dnipro, Ukraine; Email: olbelava@gmail.com

Article History

Received: 16 July 2020

Reviewed: 17/July/2020 to 02/September/2020

Accepted: 03 September 2020

E-publication: 09 September 2020

P-Publication: September - October 2020

Citation

Olha Shvaratska, Victor Mavrutenkov, Tatiana Mavrutenkova. Pediatric neuroinfection caused by *Borrelia burgdorferi* and *Varicella-zoster* virus: A case report. *Medical Science*, 2020, 24(105), 3413-3420

Publication License



This work is licensed under a Creative Commons Attribution 4.0 International License.

General Note



Article is recommended to print as color digital version in recycled paper.

ABSTRACT

Background: Pediatric co-infections are an emerging problem due to their ascending prevalence and tendency to blur typical clinical presentation of particular diseases. **Case presentation:** The paper describes a verified case of *Varicella-zoster virus* and *Borrelia*

burgdorferi co-infection in a 7-year-old male patient. Neuroinfection manifested ten days after the onset of varicella episode. Acyclovir IV was initiated for acute varicella zoster encephalitis. Concerned with the progression of neurological disorders we performed additional cerebrospinal fluid PCR testing for other potential neuropathogens; *Borrelia burgdorferi* DNA was detected. The patient denied any history of tick exposure. Combination of ceftriaxone and acyclovir IV was effective. *Discussion:* Co-infection with *Varicella-zoster virus* and *B. burgdorferi* may have a permissive deleterious impact on the central nervous system with unclear mechanisms. Testing for molecular biological and/or serological markers of Lyme disease should be a standard procedure in patients with any severe neuroinfection in endemic regions regardless of anamnestic data.

Keywords: *Varicella-zoster* infection; *Borrelia burgdorferi*; Lyme disease; encephalitis; children

1. INTRODUCTION

Co-infections in children are considered to be a common pediatric problem frequently associated with a certain modification of the classic clinical presentation of the disease. Such a distorted presentation hinders accurate estimation of etiology which in turn hampers treatment and may worsen the outcome. Lyme borreliosis (LB) is caused by the complex of *Borrelia* bacteria known as *Borrelia burgdorferi sensu lato*. According to the World Health Organization (WHO) data, LB is the most common vector-borne disease in temperate zones of the northern hemisphere, and about 65500 cases are reported annually in Europe (Rizzoli et al., 2011). However, this number may be largely underestimated as many LB infections remain undiagnosed. Moreover, case reporting is incomplete as many countries including Ukraine have not made LB a mandatory reportable disease (Schotthoefer and Frost, 2015). Studies worldwide elicit that the infection rates are highest among children 5 to 15 years old (Mead, 2015). Erythema migrans is a recognized early manifestation of LB which occurs in approximately two thirds of patients. If not treated with antibiotics at the early stage, the infection disseminates and the localized process transforms into a systemic disease with articular, neurological and, less commonly, cardiological manifestations (Biesiada et al., 2012; Steere et al., 2016).

Varicella, a typical form of primary *Varicella-zoster virus* (VZV) herpetic infection, is not a universally notifiable disease as well. Standardized annual incidence rates from 300–1291 per 100,000 populations have been reported in Europe (Riera-Montes et al., 2017; Mézner et al., 2019). Varicella is extremely common in Ukraine due to low public immunization rate (VZV vaccination is beyond the routine immunization schedule). According to some epidemiological studies conducted in non-immunized populations, up to 80 % of children fewer than 10 years of age contract varicella infection if no vaccination is provided (Wutzler et al., 2017). Primary VZV infection mainly demonstrate benign clinical course in children, however, serious complications are still an issue (Bozzola and Bozzola, 2016). In accordance with the WHO global estimates, about 4.2 million hospitalizations due to severe complications including central nervous system (CNS) related are executed every year and 4200 related fatalities are registered worldwide annually (WHO, 2014).

Given all the above, there is a substantial probability of simultaneous infection with VZV and *B. burgdorferi*, which may lead to atypical manifestations of the disease, accelerated risk of complications and uncertainty in the outcome prediction in case of such co-infection. Hence, a report describing a case of severe cerebral coma caused by VZV and *B. burgdorferi* co-infection in a child may become a point of a particular interest for many medical practitioners, thus *aiming* to facilitate management of pediatric patients with CNS infections.

2. CASE PRESENTATION

Patient information and history

A 7-year-old male child was brought to Pediatric City Clinical Hospital №6, one of the secondary healthcare level municipal children hospitals in Dnipro, Ukraine, because of vomiting, headache and confusion on the fifteenth day after the onset of varicella episode, on June 24, 2018. Two weeks prior to the admission the child presented to his local primary care facility with disseminated vesicular rash and fever, where the course of varicella infection was regarded as benign and the child started symptomatic treatment at home with no antiviral therapy. He performed grossly well, fever resolved in one day, and since the tenth day of the disease no new vesicular elements occurred. However, parents noted that the child remained to seem weak and less active than normally. Three days prior to the admission the child developed drowsiness and a headache. Immediately before admission recurrent vomiting, lethargy and poor response occurred, as reported by parents. The patient's past medical history was unremarkable. Although he received all the routine vaccinations within the national schedule, his immunization history may not be considered as complete as VZV immunization is not mandatory in Ukraine.

Vitals

On presentation on admission the child was ill-appearing, toxic, afebrile, dehydrated, with altered mental status. No spontaneous motor activity but muscle hypotonia were present. We registered transient anisocoria and poor light reflex, nystagmus. The level of consciousness assessed by the Pediatric Glasgow Coma Scale (PGCS) was estimated at the total score of 10 points (eye opening to verbal command, best motor response – flexion-withdrawal, best verbal response – inappropriate words). Meningeal irritation signs were negative. An examination revealed vast elements of varicella rash at the different stages of regression, namely crusts and pigmentation, with no new vesicles found. We observed no peripheral edema or hemorrhages. Body temperature was 36.6°C.

Upon the examination of the cardiovascular and respiratory system, the child presented with tachycardia 120 beats per minute, his blood pressure was 115/75 mmHg. Although normal saturation on room air was still maintained (SpO₂ – 98 %), spontaneous breathing was poor with episodes of apnea, which justified the necessity for admission to the Pediatric Intensive Care Unit (PICU) and artificial cardiorespiratory support. Abdominal examination was unremarkable. VZV-associated encephalitis was suspected and, consequently, intravenous (IV) acyclovir along with supportive management was started immediately after admission. Albeit, within the first day in the PICU the child developed several episodes of focal seizures and the PGCS score checked when weaning medication-assisted sedation progressively dropped to 4 (eye opening to pain only, no motor or verbal response).

Diagnostic assessment

Table 1 illustrates the main laboratory findings obtained during laboratory diagnostic evaluation process. Complete blood count (CBC) elicited non-specific inflammatory changes which gradually evolved from a clear neutrophil predominance on admission to lymphocyte predominance in a leukocyte formula a week later. Serum electrolytes and acid-base status evaluation on admission showed no major changes except for relatively low serum sodium level. Normal coagulation pattern was also revealed. Cerebral spinal fluid (CSF) analysis detected a lymphocyte-prevalent pleocytosis. Concerned with the severity and rapid progression of neurological disorders we performed additional PCR CSF testing for a set of potential encephalitis related pathogens other than VZV. CSF PCR traced *Borrelia burgdorferi* DNA thus verifying co-infection. In the patient, however, no relevant history of tick exposure or erythema migrans was confirmed.

Main results of imaging and electrophysiological studies are represented in Table 2. Cerebral computed tomography (CT) was unavailable on demand and for this reason was performed rather late, against confident positive dynamics. Multifocal hypodense lesions revealed on the cerebral CT scan were interpreted as remains of encephalitic foci (as illustrated in the figures 1 and 2).

Table 1 Main laboratory data obtained during diagnostic evaluation

Date / Day after admission	Test	Results
June 24, 2018 / 1	Complete blood count	Red blood cell count 4.1×10^{12} /L, Hemoglobin 126 g/L, Hematocrit 0.35, White blood cell count 7.1×10^9 /L; Band neutrophils 4 %, Segmented neutrophils 57 %, Lymphocytes 30 %, Eosinophils 2 %, Monocytes 7 %, Platelets 274×10^9 /L, Erythrocyte sedimentation rate 16 mm/h
June 24, 2018 / 1	Blood chemistry and serum electrolytes	Glucose 5.4 mmol/L; C-reactive protein: <6 mg/L; Total protein 67.1 g/L; Serum creatinine 90.4 umol/L; Alanine aminotransferase 12.2 U/L; Aspartate aminotransferase 20.9 U/L; Amylase 34.9 U/L; Serum electrolytes: Sodium 133 mmol/L; Potassium 3.6 mmol/L; Calcium ionized 1.2 mmol/L; Bicarbonates 25.3 mmol/L; pH 7.39.
June 24, 2018 / 1	Coagulation tests	Clotting time 3'15"; Fibrinogen 3.1 g/L; Prothrombin index 91 %
June 24, 2018 / 1	CSF analysis	Color - Transparent, Protein 0.09 g/L, Glucose 3.8 mmol/L, Cell count: 17 / mcL (neutrophils - 2, lymphocytes - 12, monocytes - 2, macrophages - 1).
June 24, 2018 / 1	Blood, CSF, urine cultures	Negative
June 27, 2018 / 4	Complete blood count	Red blood cell count 4.2×10^{12} /L, Hemoglobin 130 g/L, Hematocrit 0.39, White blood cell count 12.3×10^9 /L; Band neutrophils 2 %, Segmented neutrophils 70 %,

		Lymphocytes 22 %, Monocytes 6 %, Platelets 315×10^9 /L, Erythrocyte sedimentation rate 22 mm/h
June 30, 2018 / 7	Complete blood count	Red blood cell count 4.1×10^{12} /L, Hemoglobin 128 g/L, Hematocrit 0.38, White blood cell count 7.2×10^9 /L; Band neutrophils 2 %, Segmented neutrophils 47 %, Lymphocytes 46 %, Monocytes 5 %, Platelets 287×10^9 /L, Erythrocyte sedimentation rate 13 mm/h
June 24, 2018 / 1	Serum ELISA for HIV antibodies	Negative
June 25, 2018 / 2	CSF PCR assay	<i>Herpes simplex virus type 1</i> and <i>2</i> DNA – negative; <i>Mycobacterium tuberculosis</i> and <i>M. bovis</i> DNA – negative; <i>Epstein-Barr virus</i> DNA – negative; <i>Enteroviruses</i> RNA – negative; <i>Borrelia burgdorferi sensu lato</i> DNA – positive; VZV DNA – negative.

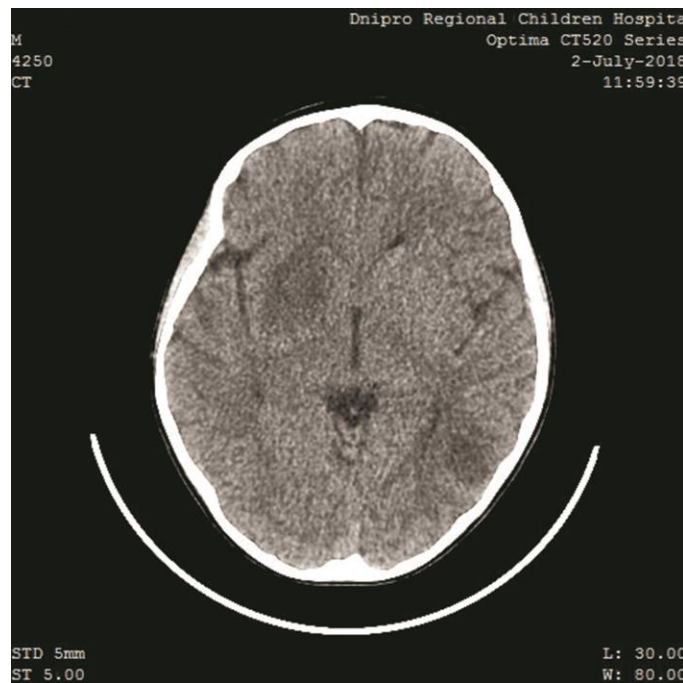

Figure 1 Cerebral CT image: The right anterior deep brain area with the compression of the lateral ventricle

Table 2 Main results of imaging and electrophysiological studies

Date / Day after admission	Test	Results
June 25, 2018 / 2	Abdominal and kidney ultrasound	No significant abnormalities
June 25, 2018 / 2	Echocardiography	Atria and ventricles are not dilated. Cardiac contractile function is sufficient. Ejection fraction is 71 %.
June 25, 2018 / 2	Electroencephalogram (EEG)	No paroxysmal electrical cerebral activity with slow and unstable basal rhythm of abnormal modality. Multiple spikes on the frontal and temporal zones.
July 2, 2018 / 9	Cerebral computed tomography (CT)	A focal hypodense area sized 27*20*26 millimeters in the basal ganglia on the right and another site of focal hypodensity with the diameter of sixteen millimeters in the left posterior temporal area, and compression of the right lateral ventricle revealed (Figures 1, 2).

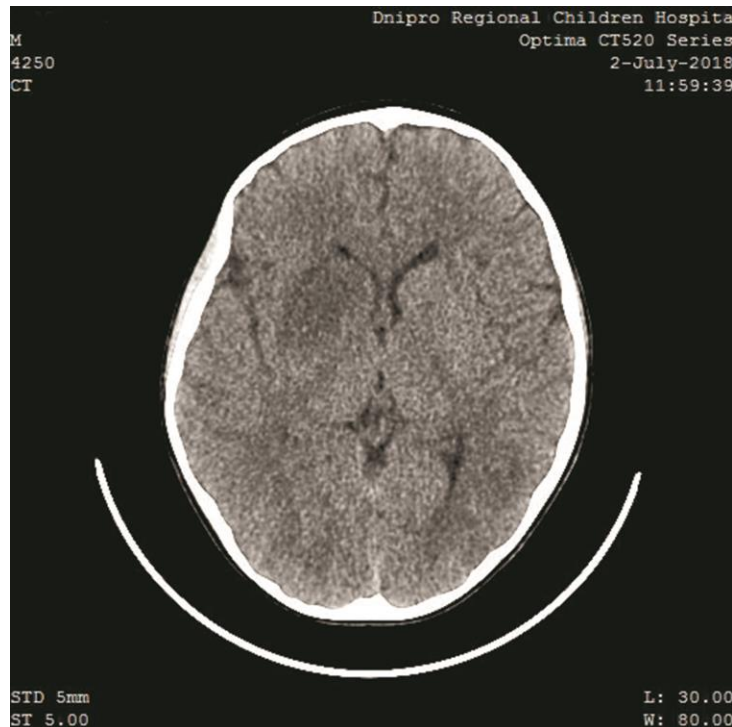


Figure 2 Cerebral CT image: A hypodense lesion in the left posterior temporal area

Treatment and interventions

As aforementioned, the child was admitted to PICU due to the necessity for artificial cardiorespiratory support. He had been on demand for the assisted ventilation in a synchronized intermittent mandatory ventilation mode for four days. Infection control was targeted with the acyclovir IV administration immediately after admission. The dose of 20 mg/kg q8hr was applied for ten days, and then it was reduced to 15 mg/kg q8hr for the following seven days and further minimized to 12.5 mg/kg q8hr for the last five days of hospital stay (twenty two days in total). Subsequently to obtaining positive CSF PCR result for *B. burgdorferi* DNA on June 25, cephtriaxone IV was added in the dose of 1.0 g q12hr for three weeks. Intravenous immunoglobulin (IVIG) was applied in the dose of 0.25 g/kg/day for 5 days according to the national standards of treatment. Specific interventions were trailed by supportive and symptomatic treatment including diazepam and mannitol.

The patient appeared to tolerate the treatment well with no adverse reactions to the medications observed. Safety monitoring comprised liver function tests, glomerular filtration rate and coagulation panel surveillance.

Follow-up and outcome

On the fourth day following admission spontaneous breathing restored. PGCS score improved to 14 points (eye opening to a verbal command). Transient anisocoria persisted. We observed a lower facial paralysis (Bell's palsy) and left-sided spastic hemiparesis. On the ninth day after admission PGCS assessment scored 15 points. No apparent focal neurological signs were registered. Cerebellar ataxia with unsteadiness while sitting and standing and inaccurate coordination tests, and slow speech were the major manifestations. Transfer to a pediatric department turned to be feasible. On July 16 the patient was transferred to a neurological department with post-encephalitic sequelae (left-sided lower spastic monoparesis and ataxia) for further follow-up and rehabilitation.

At the time of the manuscript preparation, a total follow-up period for the patient described above was two years from the date of discharge. All the motor and cognitive functions restored entirely within six months, with no signs of neurological post-encephalitic sequelae present. As of July 2020, the child is completely well and actively participates in sports activities (swimming).

3. DISCUSSION

Severe and rapid presentations, uncommon for VZV mono-infection, forced us to search for other pathogens and *B. burgdorferi* CNS infection was verified. Clinical picture of the neuroinfection discussed in the patient remains a mosaic reflection of the main conventionally recognized forms of varicella and LB CNS complications. For instance, encephalitis is a rare complication of primary

VZV infection, especially in immunocompetent children (1.7 patients per 100,000 cases (Persson et al., 2009; Lizzi et al., 2019)), manifesting during acute varicella a few days after rash onset. Clinical presentation may comprise such signs of CNS damage as lethargy, confusion, ataxia and seizures, also in some cases there may be a rapid progression to deep coma. However, usually symptoms resolve more rapidly (within 24-72 h), hemiplegia (if occurs) is usually flaccid and chronic neurologic sequelae are uncommon (Grahn and Studahl, 2015).

Likewise, acute postinfectious cerebellar ataxia is a more common complication of primary VZV infection (1:4000 cases) occurring two-three weeks after the varicella episode onset. Late manifestations in our patient such as unsteadiness/inability to stand and walk, incoordination and dysarthria may be seen as consistent with acute postinfectious cerebellar ataxia. Conversely, early signs as lethargy, confusion or coma cannot be explained with this diagnosis (Grahn and Studahl, 2015). Further, Lyme neuroborreliosis (early disseminated Lyme disease) usually manifests three-ten weeks after inoculation. Cranial neuropathy (Bell's palsy) prominent in the patient at the certain stage is quite a typical sign but encephalopathy routinely manifests with only mild confusion in combination with disturbances in memory, concentration, mood, sleep, or personality (Biesiada et al., 2012; Steere et al., 2016).

Ultimately, *Borrelia* encephalomyelitis (late Lyme disease) occurs months to years after the initial infection and progresses gradually or in a relapsing-remitting pattern. The neurologic abnormalities involve progressive spastic hemi-, para- or quadriparesis and ataxia but deep alterations of a mental status such as coma are extremely uncommon (Biesiada et al., 2012; Steere et al., 2016). Failed detection of VZV DNA in CSF with PCR assay does not exclude VZV contribution to the CNS alteration. Previous studies conducted by Levi et al. (2015) reported a noticeable part of PCR-negative cases for VZV DNA in CSF among a cluster of children with VZV-associated neurological manifestations. Similarly, De Broucker et al. (2012) demonstrated no correlation between the presence of VZV DNA in CSF and brain infection, and some authors suggest that the viral loads in CSF in the early stage of any viral encephalitis may be too low to be detected accounting for negative PCR results in case of early CSF sampling (Song et al., 2019). Another potential explanation could be the acyclovir-induced clearance of VZV DNA from the CSF to undetectable levels (De Broucker et al., 2012), as testing was performed after acyclovir treatment had been launched. For practice, concomitant skin lesions and/or history of recent (less than four weeks ago) episode of varicella infection facilitate the diagnosis of VZV-related neuroinfection and should act as a "rule of thumb" for mandatory initiation of targeted acyclovir treatment (Chai and Gong-Ruey, 2014). Thereby, we strongly believe the patient had combined viral-bacterial cause of CNS damage.

Considering the aforementioned, potential mechanisms of early and rapid development of cerebral coma with chronic neurologic sequelae in the patient are of a particular interest to discuss. Firstly, we may assume a synergic deleterious effect of LB and VZV co-infection on CNS based on shared pathogenetic pathways such as development of cerebral vasculitis with direct infectious or immune-mediated mechanisms (Zerboni et al., 2014; Grahn and Studahl, 2015; Jones et al., 2016). Further, we may speculate on the increased secretion of antidiuretic hormone (ADH) as a probable cause of coma development. ADH hypersecretion is hypothesized to be involved into pathogenesis of different neuroinfections, and of neuroborreliosis in particular (Siddiqui et al., 2017). Generally, it should be noted that rapid coma development due to ADH hypersecretion is typically reflected clinically by the presence of hyponatremia, concentrated urine and a decline in serum osmolality, and the indicated set of laboratory abnormalities may be a precondition to check for potential encephalitis related pathogens to rule out infectious causes of CNS damage.

Interestingly, the patient with an apparent varicella infection and a negative history for a tick exposure or erythema migrans had no direct clinical and historical prerequisites for *B. burgdorferi* CSF PCR testing. Despite that the isolation of borrelial DNA from CSF is a nearly unconditional proof of neuroinfection, the detection of intrathecal production of specific antibodies against *B. burgdorferi* is much more commonly used to indicate neuroborreliosis in practice. In the discussed case detection of specific antibodies was not appropriate as the patient had received IVIG which could have biased the result. Eventually, knowing the Ukrainian region as endemic justified the CSF PCR analysis for *B. burgdorferi sensu lato* DNA. We consider inclusion of testing for Lyme disease with any available method into a routine diagnostic algorithm for any severe neuroinfection in the endemic regions to be a reasonable and actionable step to improve patient care.

4. CONCLUSION

Co-infection of VZV and *B. burgdorferi* may have a permissive deleterious impact on the CNS with unclear mechanisms and is potentially life threatening. Testing for molecular biological and/or serological markers of Lyme disease should be a standard procedure in patients with any signs of severe neuroinfection in endemic areas, regardless of history data. The third generation cephalosporins in combination with acyclovir IV and IVIG may be accessible and effective first-choice-treatment option which provides a basis for a favorable prognosis.

Acknowledgement

Authors would like to express their gratitude to the patient who participated in and contributed samples to the study and to the patient's family for their kind cooperation and for acceptance of using their child's data.

Authors' contributions

Olha Shvaratska - Design of the article, data collection and analysis, draft manuscript preparation, final editing of the manuscript.
Victor Mavrutenkov - Idea and design of the article, data collection and analysis, revision of the manuscript.
Tatiana Mavrutenkova - Data collection, draft manuscript preparation.

Funding

This study has not received any external funding.

Conflict of interest

In relation to this manuscript, authors declare that there are no real or perceived conflicts of interest.

Informed consent

This paper does not contain any patient's identifying information. Written and oral informed consent was obtained from the patient and his legal representatives (parents) for the use of his medical records for research and publication benefits.

Abbreviations

ADH – Antidiuretic hormone;
CBC – Complete blood count;
CNS – Central nervous system;
CSF – Cerebral spinal fluid;
CT – Computed tomography;
DNA – Deoxyribonucleic acid;
EEG – Electroencephalogram;
ELISA - Enzyme-linked immunosorbent assay;
IV – Intravenous route of administration;
IVIG – Intravenous immunoglobulin;
LB – Lyme borreliosis;
PCR – Polymerase chain reaction;
PGCS – Pediatric Glasgow Coma Scale;
PICU – Pediatric Intensive Care Unit;
q8hr – Every 8 hours;
VZV – *Varicella-zoster virus*;
WHO – World Health Organization

Data and materials availability

All data associated with this study are present in the paper.

Peer-review

External peer-review was done through double-blind method.

REFERENCES AND NOTES

1. Biesiada G, Czepiel J, Leśniak MR, et al. Lyme disease: review. Arch Med Sci 2012;8:978-82.
2. Bozzola E, Bozzola M. Varicella complications and universal immunization. J Pediatr (Rio J) 2016;92:328-30.
3. Chai W, Gong-Ruey HM. Disseminated varicella zoster virus encephalitis. Lancet 2014;384:1698.
4. De Broucker T, Mailles A, Chabrier S, et al. Acute varicella zoster encephalitis without evidence of primary vasculopathy in a case-series of 20 patients. Clin Microbiol Infect 2012;18:808-19.

5. Grahn A, Studahl M. Varicella-zoster virus infections of the central nervous system – Prognosis, diagnostics and treatment. *J Infect* 2015;71:281-93.
6. Jones D, Blackmon A, Neff CP, et al. Varicella-zoster virus downregulates programmed death ligand 1 and major histocompatibility complex class I in human brain vascular adventitial fibroblasts, perineurial cells, and lung fibroblasts. *J Virol* 2016;90:10527-34.
7. Levy M, Hentgen V, Marque-Juillet S, et al. Prognostic value of VZV PCR in cerebrospinal fluid in neurological manifestations of varicella. *Arch Pediatr* 2015;22:491-7.
8. Lizzi J, Hill T, Jakubowski J. Varicella zoster virus encephalitis. *Clin Pract Cases Emerg Med* 2019;3:380-2.
9. Mead PS. Epidemiology of Lyme disease. *Infect Dis Clin North Am* 2015;29:187-210.
10. Mészner Z, Wysocki J, Richter D, et al. Burden of varicella in Central and Eastern Europe: findings from a systematic literature review. *Expert Rev Vaccines* 2019; 18:281-93.
11. Persson A, Bergström T, Lindh M, et al. Varicella-zoster virus CNS disease – viral load, clinical manifestations and sequels. *J Clin Virol* 2009;46:249-53.
12. Riera-Montes M, Bollaerts K, Heininger U, et al. Estimation of the burden of varicella in Europe before the introduction of universal childhood immunization. *BMC Infect Dis* 2017;17:353.
13. Rizzoli A, Hauffe HC, Carpi G, et al. Lyme borreliosis in Europe. *Eurosurveillance* 2011;16:pii=19906.
14. Schotthoefer AM, Frost HM. Ecology and epidemiology of Lyme borreliosis. *Clin Lab Med* 2015;35:723-43.
15. Siddiqui N, St. Peter DM, Marur S. Ticks and salt: an atypical case of neuroborreliosis. *J Community Hosp Intern Med Perspect* 2017;7:358-62
16. Song YX, Li Y, Jiang YM, Liu T. Detection of varicella-zoster virus from cerebrospinal fluid using advanced fragment analysis in a child with encephalitis: a case report. *BMC Infect Dis* 2019;19:342.
17. Steere A., Strle F., Wormser G., et al. Lyme borreliosis. *Nat Rev Dis Primers* 2016;2:16090
18. World Health Organization. Varicella and herpes zoster vaccines: WHO position paper. *Wkly Epidemiol Rec* 2014;89:265-87.
19. Wutzler P, Bonanni P, Burgess M, et al. Varicella vaccination – the global experience. *Expert Rev Vaccines* 2017;16:833-43.
20. Zerboni L, Sen N, Oliver SL, Arvin AM. Molecular mechanisms of varicella zoster virus pathogenesis. *Nat Rev Microbiol* 2014;12:197-210.