

**I.V. Baranov**<sup>1</sup>,  
**N.M. Nor**<sup>1,2</sup>,  
**S.V. Slesarenko**<sup>1</sup>,  
**P.O. Badiul**<sup>1,2</sup>,  
**K.V. Tsyhankov**<sup>3</sup>

## MORPHOLOGICAL FEATURES OF SKIN SCARS ON THE BACKGROUND OF TREATMENT WITH AUTOLOGOUS ADIPOCYTES

*Center of Thermal Injury and Plastic Surgery*<sup>1</sup>  
*S. Nihorian aven., 53, Dnipro, 49000, Ukraine*  
*SE «Dnipropetrovsk medical academy of Health Ministry of Ukraine»*<sup>2</sup>  
*Department of General Surgery*  
*S. Nihorian aven., 53, Dnipro, 49000, Ukraine*  
*SI «Dnipropetrovsk Clinical Hospital No. 4» DCC»*<sup>3</sup>  
*Department of Phatological Anatomy*  
*Blyzhnia str., 31, Dnipro, 49000, Ukraine*  
*Центр термічної травми та пластичної хірургії*<sup>1</sup>  
*(зав. – д. мед. н. С.В. Слесаренко)*  
*пр. С. Нігояна, 53, Дніпро, 49000, Україна*  
*ДЗ «Дніпропетровська медична академія МОЗ України»*<sup>2</sup>  
*кафедра загальної хірургії*  
*(зав.– д. мед. н. М.В. Трофімов)*  
*пр. С. Нігояна, 53, Дніпро, 49000, Україна*  
*КЗ « Міська клінічна лікарня № 4 «ДМР»*<sup>3</sup>  
*відділення патологічної анатомії*  
*(зав. – І.В. Кужевський)*  
*вул. Ближня, 31, Дніпро, 49000, Україна,*  
*e-mail: nadenor@i.ua*

**Цитування:** *Медичні перспективи*. 2020. Т. 25, № 3. С. 96-104

**Cited:** *Medicni perspektivi*. 2020;25(3):96-104

**Key words:** *fatty tissue, autolipografting, skin scars, morphological, immunohistochemical research*

**Ключові слова:** *жирова тканина, аутоліпографтинг, рубці шкіри, морфологічне, імуногістохімічне дослідження*

**Ключевые слова:** *жировая ткань, аутоліпографтинг, рубцы кожи, морфологическое, иммуногистохимическое исследование*

**Abstract. Morphological features of skin scars on the background of treatment with autologous adipocytes.** **Baranov I.V., Nor N.M., Slesarenko S.V., Badiul P.O., Tsyhankov K.V.** *So far the pathogenesis of changes and reconstruction of recipient tissues after transplantation of autologous adipocytes have not been studied sufficiently. The purpose of the research was to carry out the estimation of efficiency and morphological grounding of the surgery of transplanting autologous adipocytes for treating skin scars. The study included 35 patients (12 males and 23 females at the age of 18-55 years) with skin scars after deep burns. The majority of patients were with atrophic scars – 25 (71.4%); with hypertrophic – 8 (22.9%); with normotrophic – 2 (5.7%). To verify the processes in scar tissues the histological biopsy examination of the scar tissue was carried out; the samples were taken from patients with post-burn skin scars before and after the operation of transplanting autologous adipocytes. Sections were studied and photographed under the microscope Zeiss "Primo Star", photocalera DCM 500. To verify the mechanism of action of autoadipocytes on the reparative processes in the scar tissues, biopsy of 11 patients with atrophic scars was studied, with immunohistochemical methods of determining CD-34 + - cells with the help of monoclonal mouse antibodies to CD-34 (clone QBEnd/10) and determination of Ki-67– antigen in the nucleus of cells in all phases of the cellular cycle, except for G0 which was studied with the help of monoclonal rabbit antibodies (clone SP6), Thermo Scientific, USA. The carried out research has shown that after transplantation of autologous adipocytes in patients with post-burn scars, the process of tissue reconstruction starts in the recipient area. On the 12<sup>th</sup> and 21<sup>st</sup> day after the operation in areas of hyalinosis there was “discementing” and “separation” of collagen fibers, which may testify in favor of the probable lysis of the smallest dense hyaline deposits by the enzymes of the transplanted autologous adipocytes, in particular by lipoproteinlipasa. Thus there was a release of the skin fiber structures from lipoproteins of the blood plasma, the drainage function of the stroma and circulation of the tissue fluid were restored, intercellular communication was mitigated. In the tissue gaps which were freed from massive molecular deposits and polymers, capillaries were formed. Thus the total number of CD34 + - elements in biopsy before the operation on average was 39.3±7.3 (p<0.01), on the 14th day after the operation this indicator increased up to 53.5±11.0 (p<0.01), and on the 21<sup>st</sup> day it reached 83.4±22,8 (p<0.01), that is it has increased twice in comparison with the values before the operation. According to the results of the immunohistochemical research of the proliferative activity of Ki-67 cells in all cases the positive reaction was observed*

*exclusively in cells of the basal multi-layered keratinized squamous epithelium, cells of glandular and peloid appendages of skin. In the areas where there were CD34 + - elements among the bundles of collagen fibers, reaction with Ki-67 was negative. Only in scar biopsy on the 21<sup>st</sup> day after the operation, in hypoderm there were singular epithelioid cells near gaps with extracellular fat which had Ki-67+ reaction. The increase in the number of endothelium and other CD34+ elements testifies in favor of transformation of the transplanted autologous fat cells in endothelium and other CD34+ cells.*

**Реферат. Морфологічна характеристика рубців шкіри на фоні лікування аутологічними адипоцитами. Баранов І.В., Нор Н.М., Слесаренко С.В., Бадюл П.О., Циганков К.В.** *На сьогоднішній день недостатньо добре вивчений патогенез змін та перебудови реципієнтних тканин після пересадки аутологічних адипоцитів. Метою нашого дослідження була оцінка ефективності та морфологічне обґрунтування використання операції пересадки аутологічних адипоцитів для лікування рубців шкіри. У дослідження включено 35 пацієнтів (12 чоловіків і 23 жінки, у віці 18-55 років) з рубцями шкіри після глибоких опіків. Більшість хворих була з атрофічними рубцями – 25 (71,4%); з гіпертрофічними – 8 (22,9%); з нормотрофічними – 2 (5,7%). Для верифікації процесів у рубцевих тканинах використовували гістологічне дослідження біоптатів рубцевої тканини, які були вилучені у хворих з післяопіковими рубцями шкіри до та після операції пересадки аутологічних адипоцитів. Досліджували і фотографували зрізи під мікроскопом Zeiss "Primo Star", фотокамерою DCM 500. Для уточнення механізму дії аутоліпоцитів на репаративні процеси в рубцевих тканинах були досліджені біоптати 11 хворих з атрофічними рубцями, до яких використовували імуногістохімічні методи визначення CD-34 + - клітин за допомогою моноклональних мишачих антитіл до CD-34 (клон QVEnd/10) та визначення Ki-67 – антигену в ядрі клітин у всіх фазах клітинного циклу, окрім G0 за допомогою моноклональних кролячих антитіл (клон SP6), Thermo scientific, США. Проведене дослідження показало, що після пересадки аутологічних адипоцитів у хворих з післяопіковими рубцями починається процес перебудови тканин у реципієнтній зоні. На 14-у та 21-у добу після операції в осередках гіалінозу спостерігається «розцементування», «розклеювання» колагенових волокон, що свідчило про ймовірний лізис найменш щільних відкладень гіаліну ферментами пересаджених аутологічних адипоцитів, зокрема ліпопротеїназу. Таким чином, відбувалося звільнення волокнистих структур шкіри від ліпопротеїдів плазми крові, відновлювалась дренажна функція строми, циркуляція тканинної рідини, полегшувалась міжклітинна комунікація. У звільнених від великомолекулярних депозитів і полімерів тканинних щільностях формувались капіляри. Загальна кількість CD34 + - елементів у біоптатах до операції в середньому становила  $39,3 \pm 7,3$  ( $p < 0,01$ ) (рівень довірчої ймовірності при динамічному спостереженні), на 14 добу після операції цей показник збільшувався і становив  $53,5 \pm 11,0$  ( $p < 0,01$ ), а на 21 добу він становив  $83,4 \pm 22,8$  ( $p < 0,01$ ), тобто збільшився у два рази порівняно з показниками до операції. За результатами імуногістохімічного дослідження проліферативної активності клітин Ki 67, в усіх випадках позитивна реакція спостерігалась виключно в клітинах базального шару багатощарового зрозовілого плоского епітелію, клітинах залозистих і пілоїдних придатків шкіри. У зонах, де спостерігалась CD3 + - елементи серед пучків колагенових волокон, реакція з Ki-67 була негативною. Тільки в біоптатах рубців на 21 добу після операції, у гіподермі поодинокі епітеліоїдні клітини біля порожнин з позаклітинним жиром мали Ki-67+ реакцію. Збільшення кількості ендотелію та інших CD34 + - елементів свідчить про трансформацію переміщених аутологічних жирових клітин в ендотелій та інші CD34 + - клітини.*

In the past two decades there have been many publications in medical literature which significantly expand knowledge on features of wound healing, formation of the granular tissue and scars, their development and possibilities of controlling the process of scar formation [3, 9]. However, as for the set of main issues, there is a large number of unknown and debatable ones. According to the World Health Organization, annually in the world more than 100 million people are operated on, whereas the surgeries are of a different severity. According to different authors from 4 to 10% of the operated patients are prone to creation of colloid and hypertrophic scars, it is accompanied by not only aesthetic but psychological and social disorders as well; it also can lead to functional disorders [2, 5, 11]. In case of injuries and burns the risk for pathological scars is higher than in case of planned surgical interventions. At present, the doctor, who deals with treating scars, at estimation of morphological and functional condition of scar tissues most often relies on personal clinical experience and Vancouver Scale

[3]. There is a lack of universal devices for diagnosing scars. It also should be noted that regardless of infinite ways of treating scars, the frequency of relapses usually remains at the level of 50–70 % [5, 8, 14]. Some experience of carrying out transplantation of autologous adipocytes (autolipografting) has been accumulated in the past years, which from a routine plastic lipofilling surgery for the correction of body forms has turned into the technology of regeneration of full value [13, 15]. Application of autologous adipocytes is of great interest since these cells possess not only personal regenerative possibilities but also potential ones due to transportation of stem cells and stroma elements of fat tissue alongside autolipocytes [6, 7].

In our hospital, treatment of skin scars which appeared after burns by the method of transplanting autologous adipocytes has been applied since 2010 with profound positive clinic effect, which was confirmed by histological research [8, 12]. The present work is the continuation of morphological studies of skin scars on the background of treatment with autologous adipocytes.

The aim is estimation of efficiency and morphological grounding of the surgery of transplanting autologous adipocytes for treating skin scars.

#### MATERIALS AND METHODS OF RESEARCH

The study included 35 patients (12 males and 23 females at the age of 18-55 years) with skin scars after deep burns who were being treated from 2016 till 2019. The majority of patients were with atrophic scars – 25 (71.4%); with hypertrophic – 8 (22.9%); with normotrophic – 2 (5.7%). To verify the processes in scar tissues the histological biopsy examination of the scar tissue was carried out; the samples were taken from patients with post-burn skin scars before and after the operation of transplanting autologous adipocytes (OTAA) according to the generally accepted methodology [4]. Sampling of the material with the written consent of patients was made in the operating room under general anesthesia before OTAA and on the 14<sup>th</sup> and 21<sup>st</sup> day after the operation at stages of reconstruction weekly according to bio-rhythms, when rather clear cellular-tissue transformations take place, which in our opinion to a lesser degree can be connected with the processes of organizing alternative phenomena, caused by OTAA, which enabled us not to take samples on the 7<sup>th</sup> day. 10% neutral formalin solution was used for morphological examination; it provided comparatively good fixation of tissue parts and separate cells [4]. Main stages of histological processing included: biopsy fixation (term of fixation – 1-2 days); dehydration (dehydration of objects in absolute isopropanol) and molding in parplast; preparation of biological sections with thickness of 4-5 microns; staining of samples was with hematoxylin-eosin. Sections were studied and photographed under the microscope Zeiss "Primo Star", photcamera DCM 500. Moreover, to verify the mechanism of action of autoadipocytes on the reparative processes in the scar tissues, biopsy of 11 patients with atrophic scars was studied with immunohistochemical methods (IHC) of determining CD-34 + - cells with the help of monoclonal mouse antibodies to CD-34 (clone QBEnd/10) and determination of Ki-67– antigen in the nucleus of cells in all phases of the cellular cycle, except for G0 which was studied with the help of monoclonal rabbit antibodies (clone SP6), Thermo Scientific, USA. For the immunohistochemical examination, the sections of 4 microns in thickness were placed on adhesive slides Super Frost Plus. After standard dewaxing and rehydration, unmasking of antigen determinants was conducted in the citrate buffer with pH=6.0 in Thermo Scientific PT module at 100<sup>0</sup> C for 20 minutes. Next the sections were incubated in wet chambers with initial antibodies for 45 minutes. CD34 (dilution 1:400) and Ki-67 (dilution 1:1000)

were used as initial antibodies (Thermo Scientific, USA). To reveal the reaction the polymeric system of visualization Quanto (Thermo Scientific, USA) was used with chromo-gen 3-diaminobenzidine tetrachloride (DAB) (Thermo Scientific, USA). Sections were also unstained by hematoxylin.

Reaction with CD34 was revealed as membrane-cytoplasm brown cellular staining, which made it possible to determine the vessels, as well as formations of vascular bundles. Calculation of the number of vessels and other CD34 + - elements was made in 10 fields of vision with magnification x400 in each section.

Reaction with Ki-67 was revealed as nuclear brown staining in cells which divide or prepare for division thus it makes possible to estimate the proliferative activity of the cells. The latter was determined as percentage of cells with the reaction in 10 fields of vision (× 400) for each section.

Statistics processing of data was made using determining arithmetic mean (M) and arithmetic mean error (m). Significance of differences of mean values was determined using the Student criterion [1]. Statistical data processing was performed using a personal computer using software products STATISTICA 6.1 (StatSoftInc., Serial NAGAR909E415822FA) and Microsoft Excel (Microsoft Office 2016 Professional Plus, Open License 67528927).

#### RESULTS AND DISCUSSION

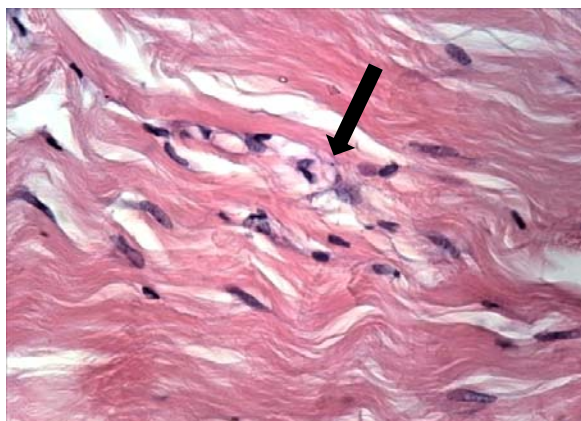
It is necessary to admit that nowadays the pathogenesis of changes and reconstruction of recipient tissues after transplantation of autologous adipocytes remains insufficiently studied. There are several theories on mechanism of action. In particular, Peer [6], who in 1950 for the first time studied physiology of lipofilling, showed that in case of isogenic transplant of the adipose tissue, its reabsorption index is 100%, whereas in case of auto-transplantation – 45%. Peer assumed that for proper engraftment of the transplanted adipose tissue there should appear a certain element of micro-angiogenesis and when it happens, the perfusion may restore for the whole block of tissues. This is the so-called cell-survival theory: human adipose transplants disappear completely for a short time after the transplantation, however small autogenous transplants have the ability to survive and one year after the transplantation they appear as normal adipose tissues. Another theory was suggested by Morrison [13]. According to this theory most transplanted adipocytes die. They create the matrix or skeleton through which the macrophages penetrate and local angiogenesis appears on it (at the expense of the stem cells). The most probable is the third one – a combined theory, according to which one part of cells survives due to the diffusion of oxygen and angiogenesis and the other part dies and provides the matrix for local cells [6, 12, 13].

In all patients with atrophic and hypertrophic scars who were studied before the transplant of autologous adipocytes, the histological picture was characterized by similar pathological changes in the form of atrophic changes of epidermis with excessive pigmentation of basal layer cells, skin appendages were sharply atrophic or they were completely absent. In derma there was roughening of bundles of collagen fibers, hyalinosis of collagen fibers which was most significantly manifested in the middle and lower third of the reticular layer, where string-shaped, strip-like areas of hyalinosis formed. In the hypertrophic scars, the areas of hyalinosis had a bigger width and density.

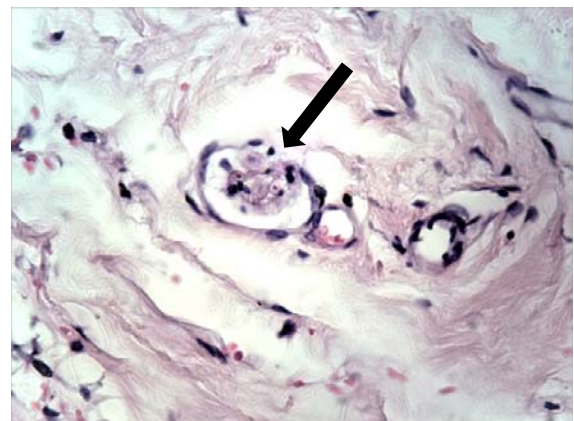
In deep layers of derma there was uneven intermediate edema with basophilia of connective tissue elements in certain areas. A large number of miscellaneous vessels and capillaries was revealed. Areas of adipose tissue with uneven, rough fibrosis were noticed in the area of transformation into hypodermis.

Biopsy of the scars on the 14<sup>th</sup> day after OTAA showed that epidermis was of an ordinary structure,

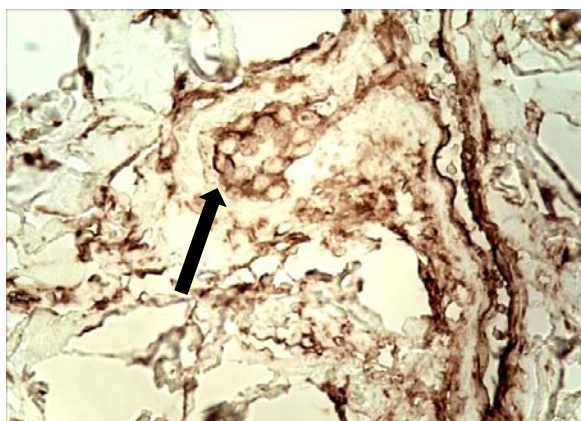
papillary and reticular derma layers were represented by unformed connective tissue with well-expressed capillary network and insignificant areas of perivascular lymphohistiocytic infiltration. Collagen fibers were well-contoured, formed a network of multidirectional bundles with clearly visible crack-like spaces between them. In the middle third of the reticular layer there were areas with moderate roughening of a part of collagen fiber bundles, the area of hyalinosis in the form of the blurred strip which appeared non-monolithic, had crack-shape gaps. Among the bundles of collagen fibers it was possible to notice groups of cells with light foamy cytoplasm (Fig. 1a); groups of round light cells with small pycnotic centrally-located nuclei were revealed in the lumen of some capillaries (Fig. 1b). At IHC-reaction with CD34, similar cells had a distinct positive membrane reaction (Fig. 3c). There were singular small areas of the granular tissue with mono- and multi-vesicular structure among them (Fig. 1d). Determination of such cellular phenomena can be indicative of the transformation of adipocytes in particular into endothelium [15].



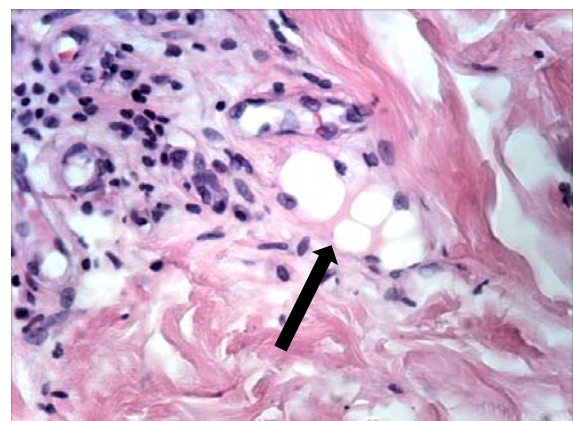
a)



b)



c)



d)

**Fig. 1.** Biopsy of the scar on the 14<sup>th</sup> day after OTAA. a) Groups of cells with light foamy cytoplasm.  $\times 400$ . Hematoxylin and eosin staining. b) The same. The group of round light cells in the capillary lumen.  $\times 400$ . Hematoxylin and eosin staining. c) The same. The group of round light cells with CD34 + membrane reaction in the capillary lumen.  $\times 400$ . Immunohistochemical reaction with CD34. d) The same. The area of the granular tissue with mono- and multi-vesicular structures.  $\times 400$ . Hematoxylin and eosin staining

On the 21<sup>st</sup> day after OTAA further changes in physical-chemical features of hyaline were noticed, which included heterogeneous staining, blurred areas of hyalinosis. There are significant features of capillarogenesis with the formation of vascular kidneys, cords of endothelium with formation of capillaries along the collagen fiber bundles and in slit-like spaces in areas of hyalinosis. Extracellular fat which was observed as small areas in hypodermis was partly resorbed by macrophages [7].

In the analysis of IHC results of the total number of CD34 + - elements in scar biopsy, statistically

significant differences were revealed ( $p > 0.01$ ) between the studied indexes before OTAA and after the surgery (Table 1).

Thus the total number of CD34 + - elements in biopsy before OTAA on average was  $39.4 \pm 7.2$ , (confidence level in the dynamic observation), on the 14<sup>th</sup> day after the surgery this indicator increased up to  $53.5 \pm 11.0$  ( $p < 0.01$ ), and on the 21<sup>st</sup> day it reached  $83.4 \pm 22.8$  ( $p < 0.01$ ) ( $M \pm m$ ), that is it increased twice in comparison with the value before the surgery.

Table 1

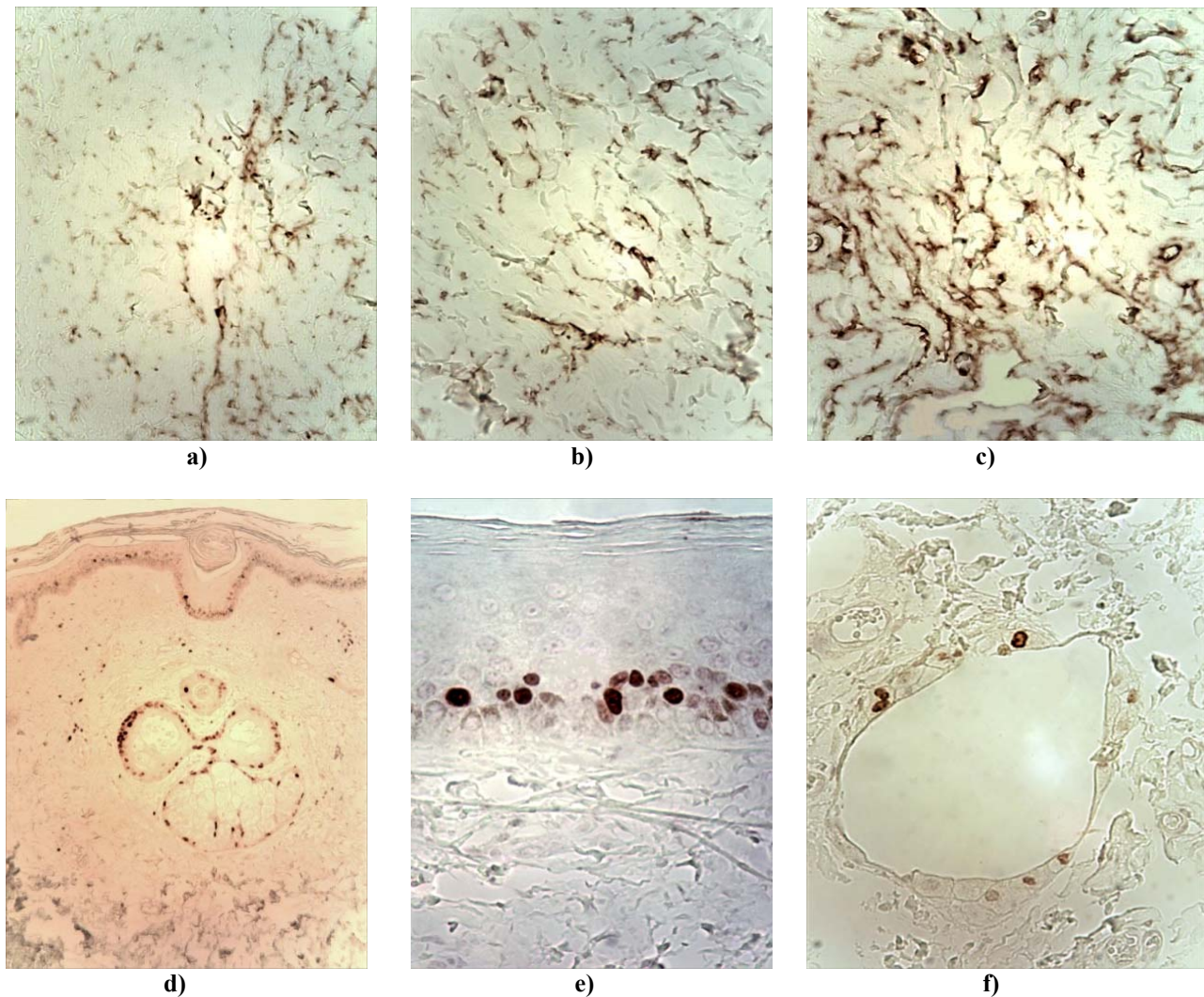
**Dynamics of immunohistochemical indexes in biopsy of scar tissues in 11 patients with atrophic scars ( $M \pm m$ )**

# of the patient	Total number of CD34+-elements in scar tissues		
	before the operation of OTAA	on the 14 <sup>th</sup> day after the OTAA	on the 21 <sup>st</sup> day after the OTAA
1	43	58	67
2	51	52	64
3	42	50	112
4	33	61	84
5	32	41	110
6	37	45	58
7	37	63	54
8	41	73	69
9	44	43	110
10	26	64	108
11	47	39	82
<b><math>M \pm m</math></b>	<b><math>39.4 \pm 7.2</math></b>	<b><math>53.5 \pm 11.0</math> (<math>p &lt; 0.01</math>), t (3.6)</b>	<b><math>83.4 \pm 22.8</math> (<math>p &lt; 0.01</math>), t (6.1)</b>

Notes:  $p < 0.01$ , t (3,6) – discrepancies according to Student's criterion in the dynamics of the number of CD34 + - elements before surgery and on the 14<sup>th</sup> day after OTAA, \*  $p < 0.01$ , t (6,1) – discrepancies according to Student's criterion in the dynamics of the number of CD34 + - elements before surgery and on the 21<sup>st</sup> day after OTAA.

Positive changes in the total number of CD34 + - elements after OTAA, in dynamics indicate the growing regenerative potential, in particular the improved blood circulation in scar tissues (Fig. 2 a, b, c). According to the results of IHC in the proliferative activity of Ki-67 cells in all cases the positive reaction was observed exclusively in cells of the basal multi-layered keratinized squamous

epithelium, cells of glandular and peloid appendages of skin. In areas where there were CD34 + - elements among the bundles of collagen fibers, reaction with Ki-67 was negative. Only in scar biopsy on the 21<sup>st</sup> day after OTAA, in hypoderm there were singular epithelioid cells near gaps with extracellular fat which had Ki-67+ reaction (Fig. 2 d, e, f).



**Fig. 2. a) Atrophic scar before OTAA.  $\times 400$ . IHC reaction with CD34. b) Atrophic scar after OTAA, 14 days.  $\times 400$  IHC reaction with CD34. c) Atrophic scar after OTAA, 21 days.  $\times 400$ . IHC reaction with CD34. d) Atrophic scar before the OTAA. Ki-67+ - cells in the basal layer of multi-layered keratinized squamous epithelium, of the sebaceous gland, atrophic hair follicle.  $\times 100$ . IHC reaction with Ki-67. e) Atrophic scar after OTAA, 14 days. Ki-67+ - cells in the basal layer of multi-layered keratinized squamous epithelium  $\times 400$ . IHC reaction with Ki-67. f) Atrophic scar after OTAA, 21 days. Ki-67+ reaction in epithelioid cells near gap with extracellular fat in hypodermis  $\times 400$ . OHC reaction with Ki-67**

As it is known, the antigen of differentiation CD-34 was initially revealed on polypotent cells-predecessors of hematopoiesis (myelopoiesis), and it was considered as a marker for those cells. However, later this agent was revealed on other cells: embryonic fibroblasts, endothelial cells of the nerve tissue. It has been determined that CD-34 +- cells are capable of differentiating into endotheliocytes, cardiomyocytes, smooth myocytes, epitheliocytes, neurons, cell neuroglia, cells of bone and cartilage tissues [9, 11]. In our study an increase in total number of CD34 + - elements was noticed in the scar tissue after OTAA at that there were no signs of the proliferate activity of cells which might testify in favor of transformation of

cells in the introduced (transplanted) adipose tissue in the endothelium and other CD34+ - cells.

#### **Clinical case.**

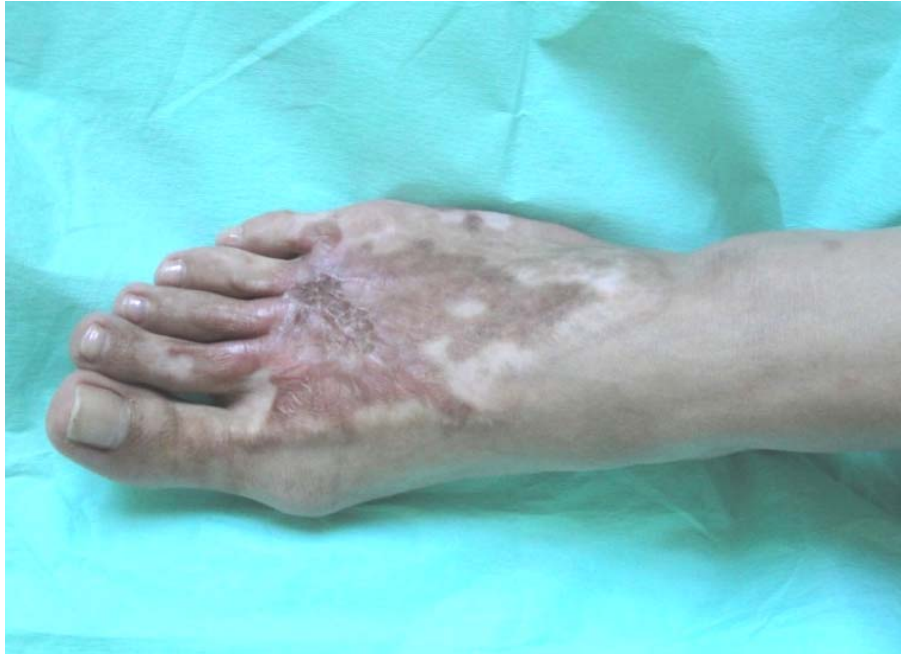A female patient K., 20 years old, was brought to at the department on the 24<sup>th</sup> of September, 2018 with the diagnosis: Atrophic scars of the left foot (Fig. 3).

Scars appeared after burn with boiling water on the 12th of May, 2018. The operation was performed on the 25th of September, 2018: OTAA scars of the left foot. The patient had IHC investigation of the scars of the left foot before the operation made, on the 14th and 21st day after OTAA. Thus the general number of CD34 + - elements in the biopsy before

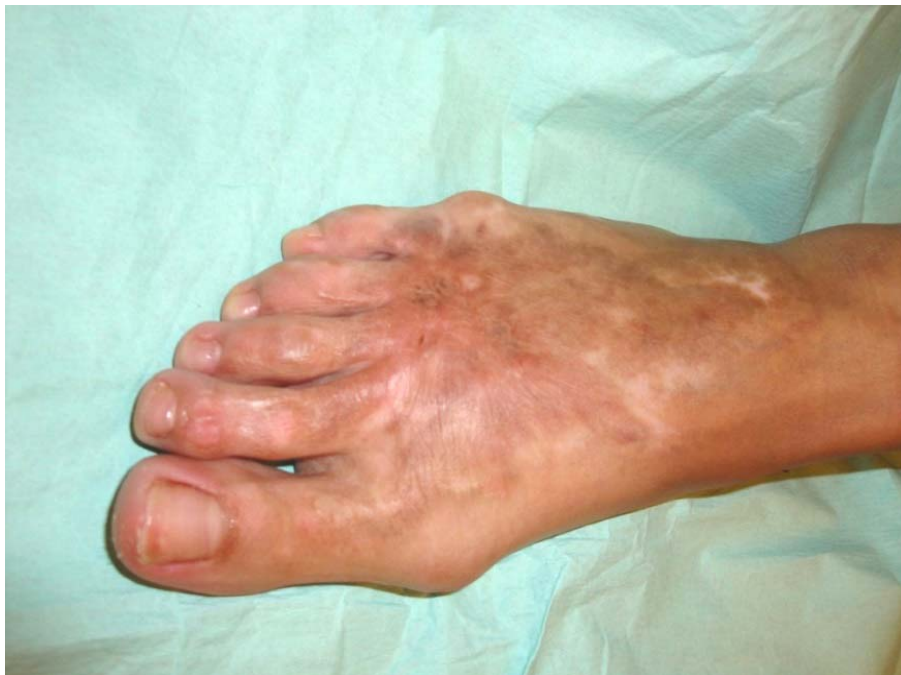ОТАА was 32, on the 14<sup>th</sup> day after the surgery this indicator increased and reached 41, on the 21<sup>st</sup> day it was 110, that is three and a half times higher than the corresponding indicator before the operation. Reaction with Ki-67 was absent. The patient was examined 6 months after the surgery. In the area of the arch of the left foot there was a significant

decrease in hyperpigmentation, increase in skin elasticity.

The range of motion in the ankle joint improved significantly. Skin mobility in the area of the scar improved. The patient noticed subjective aesthetic improvement, decrease in pain and itch, increase in mobility of the treated areas (Fig. 4).



**Fig. 3. A female patient K., 20 years old. Diagnosis: Atrophic scars of the left foot**



**Fig. 4. A female patient K., 20 years old. Diagnosis: Atrophic scars of the left foot. 6 months after OTAA**

## CONCLUSIONS

The carried out research has shown that after transplantation of autologous adipocytes in patients with post-burn scars, the process of tissue reconstruction starts in the recipient area. On the 12<sup>th</sup> and 21<sup>st</sup> day in areas of hyalinosis there is “dissecting” and “separation” of collagen fibers, which may testify in favor of the probable lysis of the smallest dense hyaline deposits by the enzymes of the transplanted autologous adipocytes, in particular by lipoproteinlipasa. Thus, to a certain extent, there is a release of the skin fiber structures from lipoproteins of the blood plasma, which are the components

of hyaline, the drainage function of the stroma and circulation of the tissue fluid are restored, intercellular communication is simplified. In the tissue gaps which were freed from massive molecular deposits and polymers, capillaries are formed, amount of endothelium and other CD34 + - elements have increased, which is indicative of the transformation of the transplanted autologous adipocytes into endothelium and other CD34 + - cells.

Conflict of interests. The authors declare no conflict of interest.

## REFERENCES

1. Antamonov MY. [Mathematical processing and analysis of medical and biological data]. Kyiv; 2017. Russian.
2. Baranov IV. [Lipofiling as a method of treating scars skins]. Plastic, reconstructive and aesthetic surgery. 2019;1-2:23-30. Ukrainian.
3. Bardova EA. [Some aspects of scarring treatment]. Dermatology and Venereology. 2015;1(67):55-62. Ukrainian.
4. Besedin AM, Tsygankov KV, Gritsenko PA. [Morphological characteristics of wounds in patients with diabetes mellitus during Vacuum therapy]. Kharkov Surgical School. 2016;1(76):47-54. Ukrainian.
5. Kovalenko AA, Kozinets GP, Kovalenko OM, et al. [The influence of surgical treatment of dermal burns on natural resistance and development of scars]. Plastic, reconstructive and aesthetic surgery. 2018;1-2:48-61. Ukrainian.
6. Smolanka II, Motuziuk IN, Sydoruk OI, et al. [Place of lipofilling in complex treatment of patients with breast cancer: history aspects and own experience]. Clinical oncology. 2015;3(19):40-44. Ukrainian.
7. Myadelets OD, Sobolevskaya IS, Myadelets VO. [Histophysiology of fat-containing skin structures]: a manual. Vitebsk: VGMU; 2015. p. 291. Russian.
8. Slesarenko SV, Baranov IV, Nor NN, Tsyhanov KV. [Reorganization of the tissue structure of skin scars when lipofilling is used]. Plastic, reconstructive and aesthetic surgery. 2019;3-4:22-31. Ukrainian.
9. Brewin MP, Homer SJ. The lived experience and quality of life with burn scarring-the results from a large-scale online survey. Burns. 2018;44:1801-10. doi: <https://doi.org/10.1016/j.burns.2018.04.007>
10. Harris WM, Plastini M, Kappy N, et al. Endothelial differentiated adipose-derived stem cells improvement of survival and neovascularization in fat transplantation. Aesthetic surgery journal. [Internet]. 2018;39(2):220-32. doi: <https://doi.org/10.1093/asj/sjy130>
11. Gal S, Ramirez JI, Maguina P. Autologous fat grafting does not improve burn scar appearance: a prospective, randomized, double-blinded, placebo-controlled, pilot study. Burns. [Internet]. 2017;43(3):486-9. doi: <https://doi.org/10.1016/j.burns.2016.09.019>
12. Badiul P, Sliesarenko S, Baranov I, et al. Lipofiling influence on the tissue structure of the skin scars. European Journal Burn Care. 2020;1:150.
13. Khouri Roger K Jr, Khouri Roger K. Current Clinical Applications of Fat Grafting. Plastic Reconstructive Surgery. 2017;3:466-86. doi: <https://doi.org/10.1097/PRS.0000000000003648>
14. Seo BF, Jung SN. The immunomodulatory effects of mesenchymal stem cells in prevention or treatment of excessive scars. Stem cells international. [Internet]. 2015;2016:8. doi: <https://doi.org/10.1155/2016/6937976>
15. Garza RM, Rennert RC, Paik KJ, et al. Studies in fat grafting: Part IV. Adipose-derived stromal cell gene expression in cell-assisted lipotransfer. Plastic Reconstructive Surgery. 2015;135:1045-55. doi: <https://doi.org/10.1097/PRS.0000000000001104>

## СПИСОК ЛІТЕРАТУРИ

1. Антамонов М. Ю. Математическая обработка и анализ медико-биологических данных. Киев. 2017 г.
2. Баранов І. В. Ліпофілінг як спосіб лікування рубців шкіри. *Пластична, реконструктивна і естетична хірургія*. 2019. №1-2. С.23-30.
3. Бардова К. О. Деякі аспекти лікування рубців. *Дерматологія та венерологія*. 2015. Т.67, № 1. С. 55-62.
4. Беседін О. М., Циганков К. В., Гриценко П. О. Морфологічна характеристика ран у хворих цукровим діабетом на фоні вакуум-терапії. *Харківська хірургічна школа*. 2016. Т. 76, № 1. С. 47-54.
5. Вплив хірургічного лікування дермальних опіків на природну резистентність і розвиток рубців /



О. А. Коваленко та ін. *Пластична, реконструктивна і естетична хірургія*. 2018. № 1-2. С. 48-61.

6. Місце ліпофілінгу в комплексному лікуванні хворих на рак грудної залози: історичні аспекти та власний досвід / І. І. Смолянко та ін. *Клиническая онкология*. 2015. Т. 19, № 3. С. 40-44.

7. Мяделец О. Д., Соболевская И. С., Мяделец В. О. Гистофизиология жиросодержащих структур кожи: пособие. Витебск: ВГМУ, 2015. 291 с.

8. Слесаренко С. В., Баранов І. В., Ноп Н. М., Циганков К. В. Реорганізація тканинної структури рубців шкіри при застосуванні ліпофілінгу. *Пластична, реконструктивна і естетична хірургія*. 2019. № 3-4. С. 22-31.

9. Brewin M. P., Homer S. J. The lived experience and quality of life with burn scarring—the results from a large-scale online survey. *Burns*. 2018. Vol. 44. P. 1801-1810. DOI: <https://doi.org/10.1016/j.burns.2018.04.007>

10. Endothelial differentiated adipose-derived stem cells improvement of survival and neovascularization in fat transplantation / W. M. Harris et al. *Aesthetic surgery journal*. 2018. Vol. 39, No. 2. P. 220-232. DOI: <https://doi.org/10.1093/asj/sjy130>

11. Gal S., Ramirez J. I., Maguina P. Autologous fat grafting does not improve burn scar appearance: a prospective, randomized, double-blinded, placebo-controlled, pilot study. *Burns*. 2017. Vol. 43, No. 3. P. 486-489. DOI: <https://doi.org/10.1016/j.burns.2016.09.019>

12. Lipofilling influence on the tissue structure of the skin scars / P. Badiul et al. *European Journal Burn Care*. 2020. No. 1. P. 150.

13. Roger K., Khouri, Jr. Roger, Khouri K. Current Clinical Applications of Fat Grafting. *Plastic Reconstructive Surgery*. 2017. No. 3. P. 466-486. DOI: <https://doi.org/10.1097/PRS.0000000000003648>

14. Seo B. F., Jung S. N. The immunomodulatory effects of mesenchymal stem cells in prevention or treatment of excessive scars. *Stem cells international*. 2016. DOI: <https://doi.org/10.1155/2016/6937976>

15. Studies in fat grafting: Part IV. Adipose-derived stromal cell gene expression in cell-assisted lipotransfer / R. M. Garza et al. *Plastic Reconstructive Surgery*. 2015. No. 135. P. 1045-1055. DOI: <https://doi.org/10.1097/PRS.0000000000001104>

Стаття надійшла до редакції  
09.04.2020

