

O.V. Poslavska<sup>1</sup>  
O.L. Statkevych<sup>2</sup>  
T.V. Svyatenko<sup>1</sup>

<sup>1</sup> Dnipro State Medical University  
<sup>2</sup> Medical Center of the Private  
Enterprise "Dzerkalo"  
Dnipro, Ukraine




Надійшла: 26.09.2025

Прийнята: 17.10.2025

DOI: <https://doi.org/10.26641/1997-9665.2025.4.74-80>

УДК: 616.517-03-007.61-091.8/-097-076.5/-079.4

## QUANTITATIVE ANALYSIS OF VASCULARIZATION, PROLIFERATION AND EXPRESSION OF ANDROGEN RECEPTORS BY EPITHELIAL SKIN CELLS IN SUBVERSIVE ABSCESSING PERIFOLLICULITIS OF THE SCALP

Poslavska O.V.  , Statkevych O.L. , Svyatenko T.V. Quantitative analysis of vascularization, proliferation and expression of androgen receptors by epithelial skin cells in subversive abscessing perifolliculitis of the scalp.



Dnipro State Medical University; Medical center of the private enterprise «Dzerkalo», Dnipro, Ukraine.


**ABSTRACT.** Introduction. Hoffmann's disease or abscessing perifolliculitis of the scalp is a chronic, therapy-resistant and recurrent purulent-inflammatory disease of the hair follicles, which causes the formation of deep abscesses, cicatricial alopecia and significant changes in the scalp. The disease occurs mainly in young men aged 20–40 years. According to the statistics of the medical center of the private enterprise "Dzerkalo", Dnipro, Ukraine, over the past ten years in Ukraine, the number of cases of abscessing perifolliculitis has begun to increase among men, especially military personnel, due to the wearing of specific protective equipment and additional factors of occlusion and inflammation of hair follicles. **The aim** of the work is to investigate stromal vascularization, proliferation and expression of androgen receptors in the epithelium of the scalp using the Fiji platform in subversive abscessing perifolliculitis of the head. **Methods.** Biopsy material from patients diagnosed with abscessing perifolliculitis of the head (Hoffmann's disease) who underwent examination and treatment at the medical center of the private enterprise "Dzerkalo", Dnipro, Ukraine was studied. All patients were men, their age ranged from 20 to 51 years, the average age was  $35.5 \pm 11.54$  years. IHC was performed according to the ThermoScientific (TS) protocols with primary antibodies to vascular endothelial cells CD34 (sp1, RTU), Ki-67 (sp6, 1:250), AR (sp1, RTU). The Lab Vision Quanto imaging system (TS, USA) was used with the reaction determination using DAB Quanto Chromogen (TS, USA). **Results.** The average number of CD-34-positive vessels showed a significant difference in the samples of subducting abscessing perifolliculitis of the scalp, compared with the control group in all studied localizations (subepidermal location, deep layers of the dermis, areas around hair follicles, areas around sebaceous glands (all  $p < 0.05$ ), with the highest number of  $24.33 \pm 3.78$  in areas around hair follicles. The average perimeter of CD-34-positive vessels showed a significant difference in the samples of subducting abscessing perifolliculitis of the scalp, compared with the control group in the deep layers of the dermis, areas around hair follicles and sebaceous glands ( $p < 0.05$ ), with the highest value of  $85.83 \pm 10.52$  in areas around hair follicles. The Ki-67 proliferation index in reactive stratified squamous epithelium at in subversive abscessing perifolliculitis of the head was  $23.46 \pm 4.24\%$ , which was statistically significantly different from the control group ( $p < 0.05$ ), whose proliferation rate remained at the level of  $5.22 \pm 1.58\%$ . In contrast, the expression of androgen receptors in the study and control groups did not show any difference ( $94.32 \pm 15.08\%$  and  $82.40 \pm 10.26\%$ , respectively,  $p > 0.05$ ), which refutes the theory of hormonal dependence of chronic inflammation in this pathology.

**Key words:** vascularization, Cd34, Ki-67, androgen receptors, abscessing perifolliculitis of the head, Hoffmann's disease, cicatricial alopecia, dermatology.

Poslavska OV, Statkevych OL, Svyatenko TV. Quantitative analysis of vascularization, proliferation and expression of androgen receptors by epithelial skin cells in subversive abscessing perifolliculitis of the scalp. *Morphologia*. 2025;19(4):74-80.

DOI: <https://doi.org/10.26641/1997-9665.2025.4.74-80>

 Poslavska O.V. 0000-0002-3133-8413;  Statkevych O.L. 0000-0003-4303-2937

 [oleksandra.poslavska@dsmu.edu.ua](mailto:oleksandra.poslavska@dsmu.edu.ua)

© Dnipro State Medical University, «Morphologia»

### Introduction

Hoffmann's disease or abscessing perifolliculitis of the scalp is a chronic, treatment-resistant and recurrent purulent-inflammatory disease of the hair follicles, which causes the formation of deep abscesses,

cicatricial alopecia and significant changes in the scalp. The disease occurs mainly in young men aged 20–40 years [1-3]. According to statistics from the medical center of the private enterprise "Dzerkalo", Dnipro, Ukraine, over the past ten years in Ukraine,

cases of abscessing perifolliculitis have begun to increase among men, especially military personnel, due to the wearing of specific protective equipment and additional factors of occlusion and inflammation of the hair follicles. Medical workers also pay attention to the seasonality of cases, namely, the number of cases in the winter-spring period exceeds the number of cases in the summer.

Despite the fact that the number of patients with abscessing perifolliculitis of the head is not high compared to the total number of patients with pustular skin lesions, due to frequent relapses and ineffectiveness of standard antibacterial therapy, cases of abscessing perifolliculitis of the head remain incorrectly diagnosed or unmonitored. In addition, Hoffmann's disease is combined with other dermatoses, such as acne conglobata or hidradenitis, which are included in the group of follicular occlusive diseases [4-7].

Due to the rarity of the pathology and the insufficient number of epidemiological studies, specific percentage prevalence rates in different countries have not been established. Unfortunately, there are also no statistical data on the prevalence of dermatosis in Ukraine. Further studies are needed to accurately determine the prevalence of abscessing perifolliculitis in different regions of the world.

Vascularization activity, proliferation and hormonal sensitivity are considered by many researchers as factors of reactivity in chronic inflammatory diseases. One of the practical ways to study vascularization is to assess the number and size of vessels by the expression of endothelial markers CD34 or CD31 by immunohistochemical method. In turn, the proliferation index and the level of androgen hormones are calculated by the nuclear expression of markers Ki-67 and AR, respectively, also by immunohistochemical staining. An objective method for assessing the processes of vascularization and proliferation can be the analysis of digital microphotographs of skin biopsy sections. Fiji is an open-source platform for analyzing images of biological objects, which was developed specifically for scientists and has a very accessible interface (the development was initiated by the author Wayne Rasband at the Research Services Branch, National Institute of Mental Health, Bethesda, Maryland, USA). The Colour Deconvolution and Immuno Ratio plugins built into Fiji allow for the analysis of preparations with the quantitative assessment of marker expression.

Considering the recurrent chronic course of abscessing perifolliculitis of the head, the uncertainty of its treatment protocols and the significant deterioration in the quality of life of patients and a significant impact on their psycho-emotional state, the study of this disease remains a relevant problem in dermatology [8-9].

**The aim** of the work is to investigate stromal vascularization, proliferation and expression of androgen receptors in the epithelium of the scalp using the Fiji platform in subversive abscessing perifolliculitis of the head.

## Materials and methods

Biopsy material from patients diagnosed with abscessing perifolliculitis of the head (Hoffmann's disease) who underwent examination and treatment at the medical center of the private enterprise "Dzerkalo", Dnipro, Ukraine was studied. All patients were male military personnel, whose age ranged from 20 to 51 years, the average age was  $35.5 \pm 11.54$  years. The diagnosis was made on the basis of clinical, anamnestic, laboratory (clinical and biochemical blood tests), instrumental (trichoscopy and dermatoscopy), microbiological and pathomorphological studies (puncture punch biopsy with histological examination in hematoxylin-eosin staining). The control group included 5 samples of clean resection margins (conditional norm) of benign nevi of the scalp of men aged 34 to 48 years, the average age was  $32.1 \pm 9.42$  years (no statistically significant difference was found compared to the study group,  $p > 0.05$ ).

The studies were performed in compliance with the main provisions of the "Rules of Ethical Principles for Conducting Scientific Medical Research with Human Participation", approved by the Declaration of Helsinki [10], orders of the Ministry of Health of Ukraine No. 690 dated 09/23/2009, No. 944 dated 12/14/2009, No. 616 dated 08/03/2012. The design of the work with information on the safety of the studies is part of the comprehensive scientific research work of the Department of Skin and Venereal Diseases of the Dnipro State Medical University "Diagnosis and Personalized Therapy of Patients with Chronic Dermatoses of Various Origins and Sexually Transmitted Infections, Taking into Account Comorbid Conditions" (State Registration No. 0122U000725, Implementation period 2022 - 2026). Approved by the Commission on Biomedical Ethics of the Dnipro State Medical University (Protocol No. 3 dated 11/16/2022).

*Morphological research method.* For histological examination, 17 blocks of formalin-fixed and paraffin-embedded puncture punch biopsies were used: 12 from the study group and 5 from the control group, which were obtained from the archive of the Dnipropetrovsk Regional Clinical Hospital named after I. I. Mechnikov in the period from April 2023 to February 2024. According to the histological structure, all observations were represented by the skin of the scalp, which corresponded to the structure of thin skin with long hair and necessarily contained epithelial and stromal 2 or more pilosebaceous units (hair follicles with adjacent sebaceous glands). In all cases, diagnostic and morphological signs were evaluated and confirmed by repeated examination by two independent pathologists. Paraffin sections of 4-5  $\mu\text{m}$  were obtained on a Microm HM-340 microtome and stained with hematoxylin and eosin according to the standard method. Two pathologists independently checked the slides for diagnostic accuracy and the presence of artifacts. Microscopy was performed using a ZEISS "Primo Star" light microscope (objectives  $\times 10$ ,  $\times 20$ ,  $\times 40$ ) [11].

**Immunohistochemical method of the study.** Paraffin sections were applied to adhesive SuperFrost Plus slides. After deparaffinization, rehydration, temperature unmasking of antigens and inhibition of endogenous peroxidase activity, sections were incubated with primary antibodies in humid chambers at a temperature of 23–25°C for 30 minutes. Primary monoclonal antibodies to Ki-67 (sp6, 1:250), AR (sp1, RTU), CD34 (sp1, RTU) and the UltraVision Quanto, LabVision imaging system were used in humid chambers for about 30 minutes at room temperature. To identify the reaction, a solution of the chromogen 3-diaminobenzidine tetrachloride (DAB) (Quanto, LabVision) was applied under microscope control for 20 seconds to 3 minutes, with the appearance of a brown color, then additionally stained with Mayer's hematoxylin for 1-3 minutes. Subsequent dehydration and inclusion in the balm were carried out according to common methods [12].

For digital morphometry, a Zeiss Primo Star - AxioCam ERC 5s microscope camera with licensed ZEN 2 blue edition software was used. The photographed fields of view were saved in .jpg format and processed in the Fiji platform with determination of the number and parameters of the perimeter and area of CD34-positive vessels in order to assess vascularization, and calculation of the percentage of Ki-67-positive and AR-positive intranuclear reactions using the ImmunoRatio plugin [13-15].

Statistical analysis of data was performed in the R software environment version 3.4.1 (2017-06-30) - "Single Candle" Copyright (C) 2017; The R Foundation for Statistical Computing Platform: x86\_64-w64-mingw32/x64 (64-bit), which is freely distributed under the GNU General Public License.

To compare the vessel perimeter, the Ki-67 proliferation index, and hormonal (AR) activity calculated by the ImmunoRatio plugin in the Fiji platform, the Shapiro-Wilk test was first used to check the normality of the distribution of the indicator in each group. In the case of a difference in distribution from normality, the nonparametric Mann-Whitney U test was used to check the difference in mean values. Differences were considered significant at  $p < 0.05$ . Data

in the tables are presented as  $M \pm SD$  (mean  $\pm$  standard deviation) [16].

### Results

In order to visualize the dermal vessels when stained with IHC using the CD34 marker in the Fiji platform, we first used the Colour Deconvolution procedure, which separates the vascular endothelium stained with DAB chromogen in brown color (*Colour Deconvolution* procedure for separating structures stained with DAB chromogen in the Fiji platform: *Image > Color > Colour Deconvolution > Vectors > H&DAB*). The final segmentation for further calculation of the vascular parameters in the skin stroma is carried out by adjusting the brightness threshold values (Threshold window), this makes the objects contrasting and clear for calculation (segmentation in the Fiji platform: *Image > Adjust > Threshold* - with adjustment of the brightness threshold values to obtain clear vessel boundaries). Further calculation of the diameter and roundness coefficient of vessels in the skin stroma in Hoffman's disease begins with calibration using a photograph of a grid with a known cell size (90  $\mu\text{m} \times 90 \mu\text{m}$ ) - converting pixels to micrometers (the calibration process in the Fiji platform using a grid with a known cell size *Analyze > Set Scale > Known distance (90  $\mu\text{m}$ ) > Global*). Next, using a tool for measuring the length of irregularly shaped objects, we manually circle the internal diameter of the vessel section to calculate their number, area in  $\mu\text{m}^2$  and diameter in  $\mu\text{m}$  (the process of measuring vessel parameters with saving results in the Fiji platform: *ROI Manager > t > Measure > Results > Summarize*).

To save measurements, we use the ROI Manager (after each stroke, press the letter t, and the corresponding record will be saved in the ROI Manager window). Pressing the Measure button gives the Results window with the values of all areas and perimeters of vessels, which can be used to calculate the average or total area, average perimeter of vessels, etc. To obtain the most reliable vascularization data from each case, three fields of view were analyzed at  $\times 400$  magnification. The mean values of the number and perimeter of vessels in the study group and in the control group are listed in Tables 1 and 2, respectively.

Table 1

Indicators of morphometric study of the number of vessels in the dermis of the skin in subversive abscessing perifolliculitis of the head,  $M \pm SD$

Skin area	Average number of CD34 (+) vessels, $M \pm SD$		
	study group, ( $n_1=12$ )	control group, ( $n_2=5$ )	p
Subepidermal location	15.64 $\pm$ 3.64	5.00 $\pm$ 0.54	$p < 0.05$
Dermal location	16.85 $\pm$ 2.56	6.38 $\pm$ 0.32	$p < 0.05$
Areas around hair follicles (external root epithelial sheath and hair dermal papilla)	24.33 $\pm$ 3.78	7.74 $\pm$ 1.05	$p < 0.05$
Around sebaceous glands	18.24 $\pm$ 4.92	6.36 $\pm$ 0.88	$p < 0.05$

Note: n – number of samples,  $M \pm SD$  – mean value  $\pm$  standard deviation, p – groups were compared by Mann-Whitney U-test.

Table 2

Indicators of morphometric study of the average perimeter of blood vessels in the dermis of the skin in subversive abscessing perifolliculitis of the head, M±SD

Skin area	Average perimeter of CD34-positive vessels (M±SD)		
	study group, (n <sub>1</sub> =12)	control group, (n <sub>2</sub> =5)	p
Subepidermal location	52.07±10.51	38.44 ±6.65	p>0.05
Dermal location	79.47±11.76	35.02 ±7.50	p<0.05
Areas around hair follicles (external root epithelial sheath and hair dermal papilla)	85.83 ±10.52	26.48 ±7.94	p<0.05
Around sebaceous glands	68.64 ±12.36	29.68 ±6.33	p<0.05

Note: M±SD – mean value ± standard deviation, p – groups were compared by Mann-Whitney U-test.

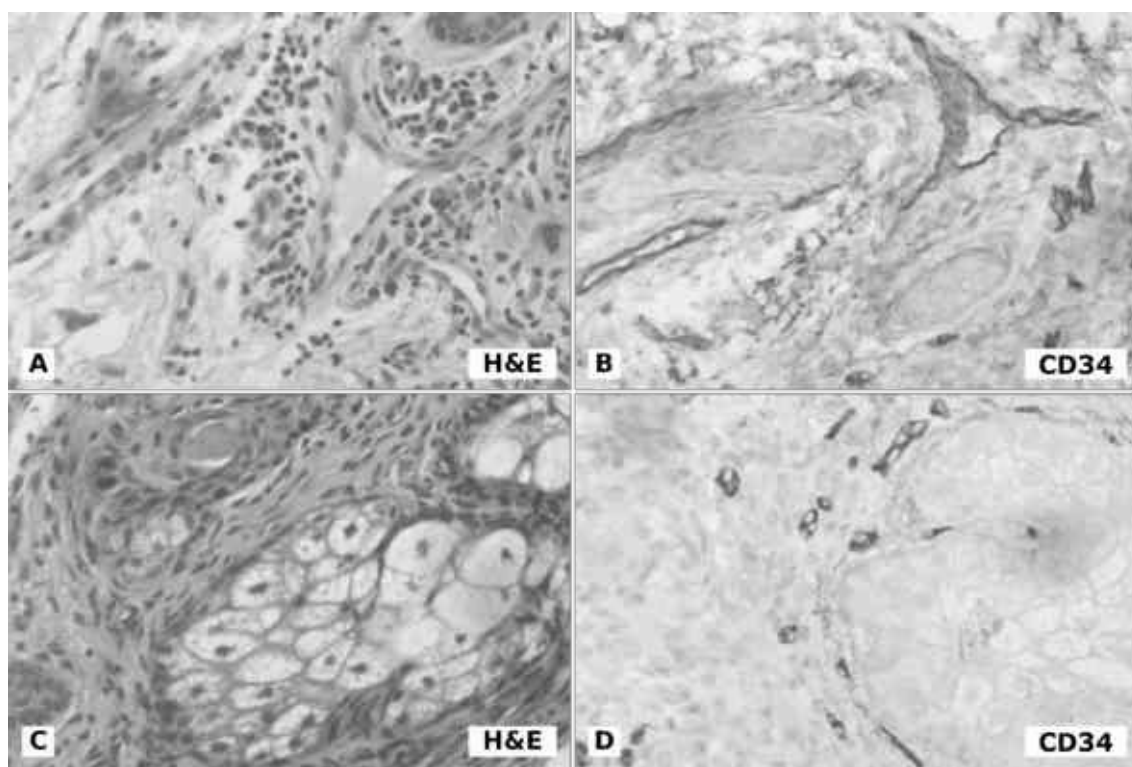


Fig. 1. A. Sample from the study group: abscessing perifolliculitis of the head (red arrows indicate large vessels, yellow arrows indicate dermal inflammatory infiltrates), H&E staining (×400). B. Abscessing perifolliculitis of the head (red arrows indicate large vessels of the dermis), expression of the CD34 marker in the vascular endothelium, IHC method with Mayer's hematoxylin (×400). C. Sample from the control group (yellow arrow indicates sebaceous gland), H&E staining (×400). D. Sample from the control group (red arrows indicate small vessels, yellow arrow indicates sebaceous gland), expression of the CD34 marker, IHC method with Mayer's hematoxylin (×400).

To understand the degree of activity of reactive proliferation of stratified squamous epithelium and the number of androgen receptors in the study group, the level of which differed compared to the control group, the expression level of Ki-67 and AR markers was automatically calculated using the ImmunoRatio plugin (Fig. 2).

The distribution of the mean values of proliferation and expression of androgen receptors in the stratified squamous epithelium of the study and control groups is listed in Table 3.

### Conclusions

1. The average number of CD-34-positive vessels showed a significant difference in the samples of

subducting abscessing perifolliculitis of the head, compared with the control group in all studied localizations (subepidermal location, deep layers of the dermis, areas around hair follicles, areas around sebaceous glands (all  $p<0.05$ ), with the highest number of  $24.33\pm3.78$  in areas around hair follicles.

2. The average perimeter of CD-34-positive vessels showed a significant difference in the samples of subducting abscessing perifolliculitis of the head, compared with the control group in the deep layers of the dermis, areas around hair follicles and sebaceous glands ( $p<0.05$ ), with the highest value of  $85.83\pm10.52$  in areas around hair follicles.

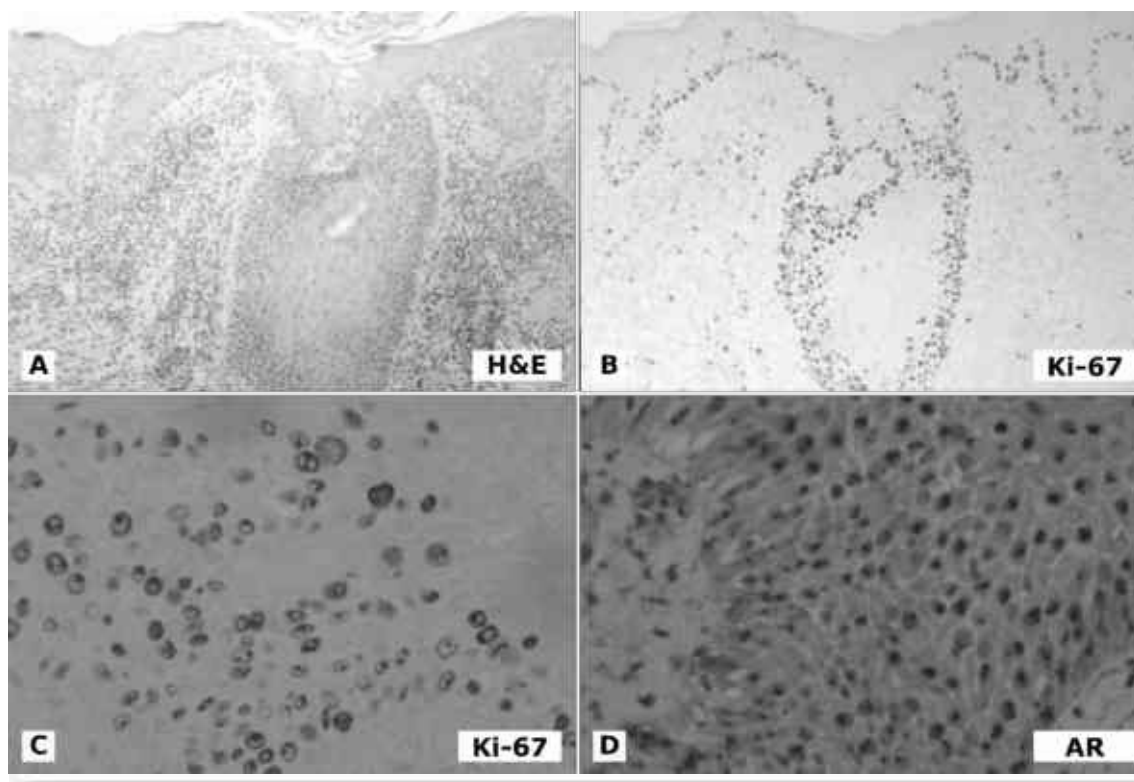


Fig. 2. Sample from the study group: abscessing perifolliculitis of the scalp. A. Massive inflammatory infiltration of subepidermal localization, multiple mitotic figures in the basal parts of the epidermis, H&E staining ( $\times 400$ ). B. Expression of the Ki-67 marker in the basal and parabasal parts of the epidermis at a level of about 10%, IHC method with Mayer's hematoxylin ( $\times 400$ ). C. Active areas of proliferation (Ki-67 expression up to 20%), IHC method with Mayer's hematoxylin ( $\times 400$ ). D. Intranuclear and cytoplasmic expression of AR in most cells of the stratified squamous epithelium (AR expression up to 90%), IHC method with Mayer's hematoxylin ( $\times 400$ ).

Table 3

Indicators of morphometric study of proliferative activity and expression of androgen receptors in the epidermis of the skin in subversive abscessing perifolliculitis of the head, %,  $M \pm SD$

Immunohistochemical index	Research groups		p
	study group, ( $n_1=12$ )	control group, ( $n_2=5$ )	
Proliferative activity by Ki-67 (%), ( $M \pm SD$ )	23.46 $\pm$ 4.24	5.22 $\pm$ 1.58	p<0.05
Androgen receptor expression, AR (%), ( $M \pm SD$ )	94.32 $\pm$ 15.08	82.40 $\pm$ 10.26	p>0.05

Note:  $M \pm SD$  – mean  $\pm$  standard deviation, p - groups were compared using the Mann-Whitney U-test.

3. Ki-67 proliferation index in reactive multi-layer squamous epithelium in subversive abscessing perifolliculitis of the head was 23.46 $\pm$ 4.24%, which was statistically significantly different from the control group (p<0.05), whose proliferation rate remained at the level of 5.22 $\pm$ 1.58%. In contrast, the expression of androgen receptors in the study and control groups did not show any difference (94.32 $\pm$ 15.08 and 82.40 $\pm$ 10.26, respectively, p>0.05), which refutes the theory of hormonal dependence of chronic inflammation in this pathology.

**Prospects for further research**

Continued study of Hoffmann's disease requires

information on the expression of  $\beta$ -catenin and E-cadherin in the structures of the pilosebaceous unit in this pathology.

**Conflict of interest information**

There are no potential or apparent conflicts of interest related to this manuscript at the time of publication and are not anticipated.

**Sources of funding**

The studies is part of the scientific research work "Diagnosis and Personalized Therapy of Patients with Chronic Dermatoses of Various Origins and Sexually Transmitted Infections, Taking into Account Comorbid Conditions" (State Registration No. 0122U000725).

## References

1. Wu Q, Bu W, Zhang Q, Fang F. Therapeutic options for perifolliculitis capitis abscedens et suffodens: A review. *Dermatol Ther.* 2022;35(10):e15763. doi: 10.1111/dth.15763.
2. Masson R, Jeong CY, Ma E, Crew AB, Frago NM, Shi VY, Hsiao JL. Treatments for Dissecting Cellulitis of the Scalp: A Systematic Review and Treatment Algorithm. *Dermatol Ther (Heidelb).* 2023;13(11):2487-526. doi: 10.1007/s13555-023-01018-7.
3. Yu Chen, Yan-Ping Yang, Fang Qiu, Yu-Jie Wang, Yi-Ming Fan, Immunophenotyping comparison of inflammatory cells between *Malassezia* folliculitis and pityriasis versicolor lesions. *Medical Mycology.* 2022;60(1):myab073. doi: 10.1093/mmy/myab073.
4. Melo DF, Lemes LR, Pirmez R, Duque-Estrada B. Trichoscopic stages of dissecting cellulitis: a potential complementary tool to clinical assessment. *An Bras Dermatol.* 2020;95(4):514-17. doi: 10.1016/j.abd.2019.10.008.
5. Scheinfeld N. Dissecting cellulitis (perifolliculitis capitis abscedens et suffodiens): a comprehensive review focusing on new treatments and findings of the last decade with commentary comparing the therapies and causes of dissecting cellulitis to hidradenitis suppurativa. *Dermatol Online J.* 2014;20(5):22692.
6. Wolff H, Fischer TW, Blume-Peytavi U. The Diagnosis and Treatment of Hair and Scalp Diseases. *Dtsch Arztebl Int.* 2016;113(21):377-86. doi: 10.3238/arztebl.2016.0377.
7. Calonje E, Brenn T, Lazar A, Steven D. Billings McKee's Pathology of the Skin with Clinical Correlations, 5th Edition. Elsevier; 2019. 1980 p.
8. Cuellar TA, Roh DS, Sampson CE. Dissecting cellulitis of the scalp: a review and case studies of surgical reconstruction. *Plast Reconstr Surg Glob Open.* 2020;8(8):e3015. doi:10.1097/GOX.0000000000003015.
9. Takahashi T, Yamasaki K, Terui H, et al. Perifolliculitis capitis abscedens et suffodiens treatment with tumor necrosis factor inhibitors: a case report and review of published cases. *J Dermatol.* 2019;46(9):802-7. doi:10.1111/1346-8138.14998.
10. World Medical Association. World Medical Association Declaration of Helsinki: ethical principles for medical research involving human subjects. *JAMA.* 2013;310(20):2191-4. doi: 10.1001/jama.2013.281053.
11. Vareniuk IM, Dzerzhynskiy ME. [Methods of cyto-histological diagnosis]. Kyiv: Interservis. 2019. 256 p. Ukrainian.
12. Nguyen T. Immunohistochemistry: A Technical Guide to Current Practices. Cambridge: Cambridge University Press. 2022. 282 p.
13. Ma YL, Peng JY, Zhang P, et al. Immunohistochemical analysis revealed CD34 and Ki67 protein expression as significant prognostic factors in colorectal cancer. *Med Oncol.* 2010; 27:304-309. doi: 10.1007/s12032-009-9210-3.
14. Chantrain CF, DeClerck YA, Groshen S, McNamara G. Computerized quantification of tissue vascularization using high-resolution slide scanning of whole tumor sections. *J Histochem Cytochem.* 2003;51(2):151-158. doi: 10.1177/002215540305100203.
15. Schindelin J, Arganda-Carreras I, Frise E, et al. Fiji: an open-source platform for biological-image analysis. *Nature Methods.* 2012;9(7):676-682. doi: 10.1038/nmeth.2019.
16. Petrovska I, Salyha Y, Vudmaska I. [Statistical methods in biological research: educational and methodological manual]. Kyiv: Agrarian science; 2022. 172 p. Ukrainian.

**Пославська О.В., Статкевич О.Л., Святенко Т.В. Кількісний аналіз васкуляризації, проліферації та експресії андрогенових рецепторів епітеліальними клітинами шкіри при підриваючому абсцедуючому перифолікуліті голови.**

**РЕФЕРАТ.** Вступ. Хвороба Гофмана або перифолікуліт голови абсцедуючий є хронічним стійким до терапії та рецидивуючим гнійно-запальним захворюванням волосяних фолікулів, що викликає утворення глибоких абсцесів, рубцевої алопеції і значних змін шкіри голови. Захворювання зустрічається переважно у молодих чоловіків у віці 20–40 років. За статистичними даними медичного центру приватного підприємства «Дзеркало», Дніпро, Україна, за останні десять років в Україні звернення з приводу абсцедуючого перифолікуліту почала рости серед чоловіків, особливо військовослужбовців, у зв'язку з носінням спеціального захисного обладнання та додатковими факторами оклюзії та запалення волосяних фолікулів. **Мета** роботи – дослідити стромальну васкуляризацію, проліферацію та експресію андрогенових рецепторів у епітелії шкіри голови за допомогою платформи Фіджі при підриваючому абсцедуючому перифолікуліті голови. **Методи.** Досліджено біопсійний матеріал пацієнтів з діагнозом перифолікуліт голови абсцедуючий (хвороба Гофмана), що проходили обстеження та лікування на базі медичного центру приватного підприємства «Дзеркало», Дніпро, Україна. Всі пацієнти були чоловіками, вік яких коливався від 20 до 51 років, середній вік склав  $35,5 \pm 11,54$  років. ІГХ проводили за протоколами TermoScientific (TS) з первинними антитілами до ендотеліальних клітин судин CD34 (sp1, RTU), Ki-67 (sp6, 1:250), AR (sp1, RTU). Ви-

користували систему візуалізації Lab Vision Quanto (TS, США) з визначенням реакції за допомогою хромогену DAB Quanto Chromogen (TS, США). **Результати.** Середня кількість CD-34-позитивних судин показала достовірну різницю в зразках підриваючого абсцедуючого перифолікуліту голови, порівняно з контрольною групою по всім дослідженим локалізаціям (субепідермальне розташування, глибокі шари дерми, ділянки навколо волосяних фолікулів, ділянкам навколо сальних залоз (всі  $p < 0,05$ ), з найбільшою кількістю  $24,33 \pm 3,78$  в ділянках навколо волосяних фолікулів. Середній периметр CD-34-позитивних судин продемонстрував достовірну різницю в зразках підриваючого абсцедуючого перифолікуліту голови, порівняно з контрольною групою в глибоких шарах дерми, ділянках навколо волосяних фолікулів та сальних залоз ( $p < 0,05$ ), з найбільшим значенням  $85,83 \pm 10,52$  в ділянках навколо волосяних фолікулів. Індекс проліферації за Ki-67 в реактивному багатошаровому плоскому епітелії при підриваючому абсцедуючому перифолікуліті голови складав  $23,46 \pm 4,24$  %, що статистично достовірно відрізнявся від групи контролю ( $p < 0,05$ ), чий показник проліферації залишався на рівні  $5,22 \pm 1,58$  %. Натомість, експресія андрогенових рецепторів в групах дослідження та контролю різниці не показала ( $94,32 \pm 15,08$  та  $82,40 \pm 10,26$ , відповідно,  $p > 0,05$ ), що спростовує теорію гормональної залежності хронічного запалення при цій патології.

**Ключові слова:** васкуляризація, Cd34, Ki-67, андрогенові рецептори, перифолікуліт голови абсцедуючий, хвороба Гоффмана, рубцова алопеція, дерматологія.