

Ya.P. Nahirnyi,<sup>ORCID</sup>  
N.O. Tverdokhlib\*,<sup>ORCID</sup>  
I.V. Stefaniv<sup>ORCID</sup>

## A CASE REPORT OF FACIAL SKIN NECROSIS FOLLOWING COVID-19 INFECTION

I. Horbachevsky Ternopil National Medical University  
Maidan Voli, 1, Ternopil, 46001, Ukraine  
Тернопільський національний медичний університет ім. І.Я. Горбачевського  
Міністерства охорони здоров'я України  
вул. Майдан Волі, 1, Тернопіль, 46001, Україна  
\*e-mail: [tverdohlibno@tdmu.edu.ua](mailto:tverdohlibno@tdmu.edu.ua)

**Цитування:** *Медичні перспективи*. 2025. Т. 30, № 4. С. 61-67

**Cited:** *Medicni perspektivi*. 2025;30(4):61-67

**Key words:** *facial skin necrosis, COVID-19, plastic defect closure*

**Ключові слова:** *некроз шкіри обличчя, COVID-19, пластичне закриття дефекту*

**Abstract.** A case report of facial skin necrosis following COVID-19 infection. Nahirnyi Ya.P., Tverdokhlib N.O., Stefaniv I.V. The article presents data from a clinical case that illustrates potential complications of COVID-19, in particular thrombotic phenomena in the skin and soft tissues, which can lead to necrosis even in the long term. Timely detection and comprehensive treatment provide a chance to avoid deep cicatricial facial deformities. The COVID-19 coronavirus infection, which has emerged in recent years, leads to a number of complications in various organs and systems, in the pathogenesis of which the determining factors are reduced immunity and circulatory disorders. Recently, there have been reports of complications in the maxillofacial region, such as osteonecrosis of the jaws, damage to the mucous membrane, cases of deformation of the facial bones, osteomyelitis, thrombosis of the cavernous sinuses, as well as a tendency to increase in the number of malignant tumors of the maxillofacial region. The aim of the work was to demonstrate a clinical case of facial skin necrosis in a patient who had COVID-19, to improve the diagnostic process, and raise awareness of possible rare complications of coronavirus infection. A clinical case of a patient who was admitted to the Department of Surgical Dentistry from the Intensive Care Unit with complaints of a facial wound that appeared after surgery for extensive swelling of the skin of the right half of the face is described. The COVID-19 test was positive. In a few days, the patient experienced progression of skin and subcutaneous fat necrosis, which led to a soft tissue defect. After the treatment, including surgical interventions and drug therapy, the patient's condition improved. The literature review also addressed the mechanisms of COVID-19 complications, including vasculitis, microthrombosis, and the effect on the immune system, which contribute to the development of necrotic changes. Timely diagnosis and adequate treatment of COVID-19 complications, especially rare manifestations such as skin necrosis, are important to prevent further progression of the pathological process and improve the prognosis for the patient. Close monitoring of patients who have had COVID-19, especially those with risk factors, is key to early detection and effective management of such complications. A 69-year-old patient was admitted to the Department of Surgical Dentistry from the Intensive Care Unit with complaints of a facial wound that developed following surgery for extensive swelling of the skin on the right side of the face. The COVID-19 test was positive. A few days after admission, despite ongoing antibacterial therapy, the wound became covered with extensive necrotic tissue without signs of spontaneous rejection. Due to the size of the affected area, a two-stage necrectomy was performed, followed by free skin grafting harvested from the anterior thigh. The postoperative period was uneventful, and the grafted skin flaps successfully integrated. The patient was discharged for continued follow-up under the care of a family doctor.

**Реферат.** Клінічний випадок некрозу шкіри обличчя на тлі перенесеного Covid-19. Нагірний Я.П., Твердохліб Н.О., Стефанів І.В. У статті наведені дані клінічного випадку, який ілюструє потенційні ускладнення COVID-19, зокрема тромботичні явища в шкірі та м'яких тканинах, що можуть призвести до некрозу навіть у віддаленому періоді. Своєчасне виявлення та комплексне лікування дають шанс на уникнення глибоких рубцевих деформацій обличчя. Коронавірусна інфекція COVID-19, що з'явилась в останні роки, призводить до ряду ускладнень з боку різних органів і систем, у патогенезі розвитку яких визначальними факторами є зниження імунітету та порушення кровообігу. Останнім часом з'явилися повідомлення про виникнення таких ускладнень у щелепно-лицевій ділянці, як остеонекроз щелеп, ураження слизової оболонки, випадки деформації кісток лицевого черепа, остеомиєліт, тромбоз кавернозних пазух, а також тенденція до збільшення кількості злоякісних пухлин щелепно-лицевої ділянки. Метою роботи було продемонструвати клінічний випадок некрозу шкіри обличчя в пацієнта, який переніс COVID-19, для покращення діагностичного процесу та підвищення обізнаності про можливі рідкісні ускладнення коронавірусної інфекції. Описано клінічний випадок пацієнта, який

надійшов до відділення хірургічної стоматології з палати інтенсивної терапії зі скаргами на наявність рани обличчя, що з'явилася після хірургічного втручання з приводу обширного набряку шкіри правої половини обличчя. Тест на COVID-19 був позитивний. Через деякий час у пацієнта спостерігалось прогресування некрозу шкіри та підшкірно-жирової клітковини, що призвело до дефекту м'яких тканин. Після проведеного лікування, включаючи хірургічні втручання та медикаментозну терапію, стан пацієнта покращився. Аналіз літератури також розглянув механізми виникнення ускладнень COVID-19, включаючи васкуліт, мікротромбоз та вплив на імунну систему, що сприяють розвитку некротичних змін. Своєчасна діагностика та адекватне лікування ускладнень COVID-19, особливо рідкісних проявів, таких як некроз шкіри, є важливим для запобігання подальшому прогресуванню патологічного процесу та покращення прогнозу для пацієнта. Уважне спостереження за пацієнтами, які перенесли COVID-19, особливо тими, що мають фактори ризику, є ключовим для раннього виявлення та ефективного управління такими ускладненнями. У відділення хірургічної стоматології надійшов хворий (69 років) з палати інтенсивної терапії зі скаргами на наявність рани обличчя, яка виникла після проведення хірургічного втручання з приводу обширного набряку шкіри правої половини обличчя. Тест на COVID-19 був позитивний. Через декілька днів після надходження, на тлі антибактеріальної терапії, рана покрилась масивними некротичними масами без тенденції до відторгнення. Враховуючи величину ураженої ділянки, була проведена некректомія у два етапи, з вільною пластикою шкіри, взятої з передньої поверхні стегна. Післяопераційний період перебігав без ускладнень, пересажені шкірні клапти прижились без ускладнень. Хворий виписаний для подальшого спостереження в сімейного лікаря.

The COVID-19 coronavirus infection, which appeared in the world in 2019, can not only have a severe course, but, in some cases, lead to the development of many complications, including skin necrosis. Thus, in the literature, there are reports of necrosis of the foot, fingers on the lower and upper extremities [1, 2, 3, 4, 5, 6]. There have been reports of complications in the form of necrosis of the upper jawbone after COVID-19 [2, 7, 8], lesions of the mucous membrane that occur before or simultaneously with other skin manifestations, and cases of deformation of the facial skull bones, osteomyelitis, and thrombosis of the cavernous sinuses have also been recorded. Some studies indicate a tendency to increase the number of malignant tumors of the maxillofacial region. Given the high mutation rate of the virus, its elimination from the population is not possible [9, 10, 11, 12], we should expect an increase in dental patients with complications of post-covid infection, so we want to share clinical observation of the course and treatment of a 69-year-old patient with facial skin necrosis, which occurred after infection with coronavirus infection. A thorough search in the literature of the bibliographic and abstract databases Scopus, the Web of Science platform, and the electronic database PubMed did not allow us to find similar cases of necrosis.

The aim is to familiarize practitioners of the dental community with the problem of diagnosing and treating facial skin necrosis against the background of COVID-19, using the example of our own clinical case.

The COVID-19 pandemic, caused by the SARS-CoV-2 virus, has become a global challenge for healthcare systems, causing not only respiratory, but also numerous extrapulmonary complications. One of such complications, which is gaining increasing attention, is skin lesions, in particular the development of ischemic changes and necrosis. Although

most dermatological manifestations of COVID-19 are benign, in some cases, severe lesions with necrotic changes occur, associated with impaired microcirculation, small vessel thrombosis, or vasculitis.

The development of facial skin necrosis is of particular clinical importance, as it may result not only in severe medical complications but also in significant psychological and aesthetic impacts for the patient. The description of such cases is important for a deeper understanding of pathogenetic mechanisms, timely diagnosis, and optimization of treatment approaches.

This article presents a clinical case of facial skin necrosis in a patient following COVID-19, with a discussion of the probable pathogenetic mechanisms, diagnostic approach, and treatment strategies. Free skin grafting for the closure of extensive defects that developed after COVID-19 infection appears to be the most promising treatment method for this category of patients.

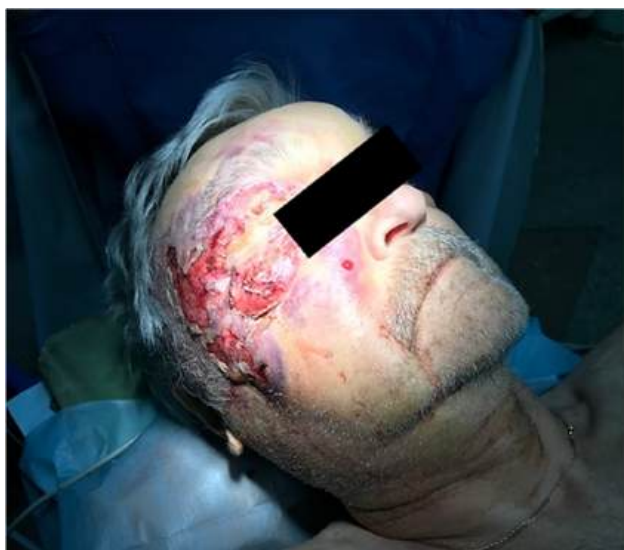#### MATERIALS AND METHODS OF RESEARCH

From February 28, 2023, to April 25, 2023, patient M., 69 years old, was treated in the Department of Surgical Dentistry with the following diagnosis: skin-fascial necrosis of the right half of the face on the background of hemorrhagic disorders as a consequence of post-COVID syndrome. Accompanying conditions included hypochromic anemia of moderate severity, severe pulmonary hypertension, congenital heart disease with atrial septal defect, rhythm disturbance of the atrial fibrillation type, and chronic heart failure, stage II, type B, with ascites.

The study was conducted in accordance with the principles of Bioethics set forth in the Declaration of Helsinki, "Ethical Principles of Medical Research Involving Humans," and the "Universal Declaration on Bioethics and Human Rights (UNESCO) (protocol

No. 21 dated 09/18/2024). The study materials were discussed and approved by the Commission on Bioethical Expertise and Ethics of Scientific Research at the I. Horbachevsky Ternopil National Medical University (excerpt from protocol No. 81 dated 04/03/2025). Written informed consent for publication was obtained from the patient.

Upon admission, the patient complained of an extensive wound on the right side of the face, swelling, general malaise, pain in the right eye, and restricted mobility of the right eyelids (Fig. 1).

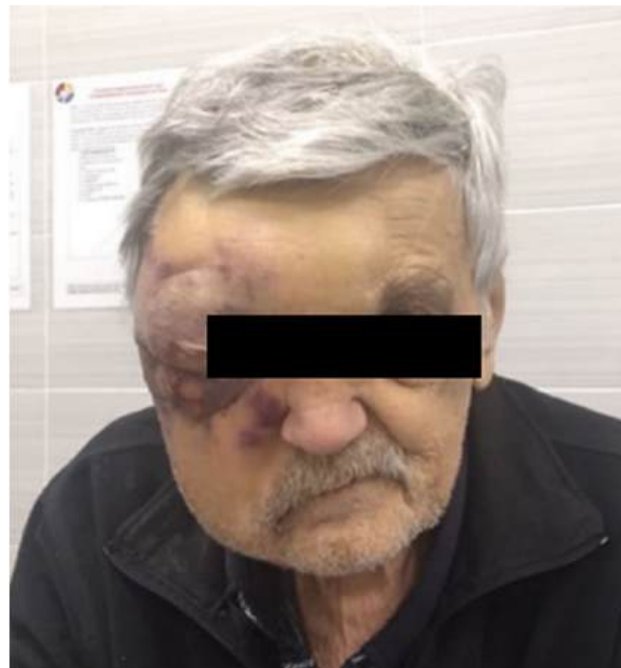

**Fig. 1. Extensive wound on the right side of the face**

From the anamnesis, it is known that from February 14 to February 22, 2023, the patient was treated in the therapeutic department of Ternopil Emergency Hospital for decompensated heart failure and was discharged in satisfactory condition. After discharge, his condition worsened: on February 24, 2023, swelling of the soft tissues in the paraorbital area developed. The family doctor diagnosed a hematoma of the zygomatic-orbital region, and the patient was admitted to the admission department of Ternopil Regional Clinical Hospital, where he was examined by an ophthalmologist, maxillofacial surgeon, and anesthesiologist. Due to the severity of his general condition, he was subsequently hospitalized in the intensive care unit.

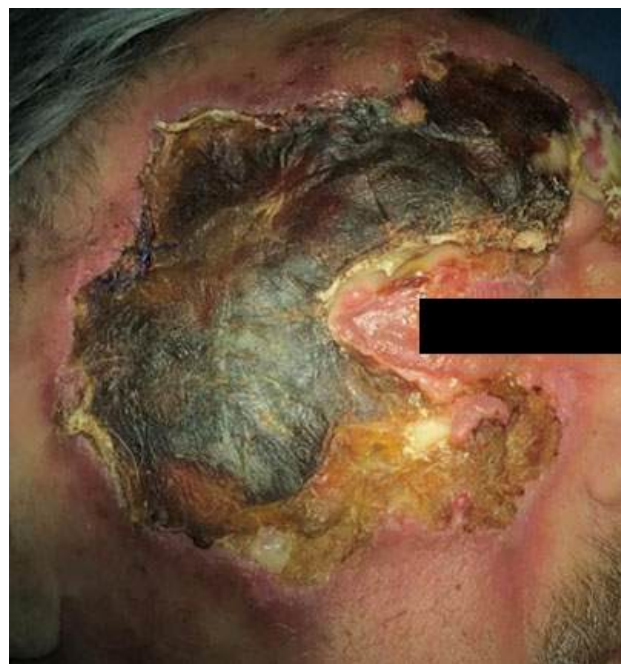A PCR test was performed in the department, the SARS-Cov-2 virus was detected and the patient was transferred to the therapeutic department of Ternopil City Clinical Hospital No. 2 (as a specialized department where patients with COVID-19 are treated). After treatment, on February 28, 2023, the PCR test was negative, and the patient was admitted to the Department of Surgical Dentistry (the local state is presented in Fig. 2), where the hematoma was

urgently opened due to the increase in edema. On autopsy, a whitish liquid was obtained.



**Fig. 2. Local state of the patient**

The next day, the swelling practically disappeared and an extensive eroded surface appeared, which in 2 days became covered with necrotic masses (Fig. 3).



**Fig. 3. Extensive eroded surface covered with necrotic masses**

The patient received modern etiologic and pathogenetic therapy in the Department of Surgical

Dentistry of the Ternopil Regional Clinical Hospital. The treatment was aimed not only at eliminating the bacterial infection, but also at correcting the anemic syndrome, maintaining the function of the cardiovascular system, reducing the severity of the inflammatory reaction, and preventing thrombosis.

In order to restore blood parameters, the patient was transfused with red blood cell mass of blood group A(II) Rh (+) and prescribed drugs to correct anemia: intravenous administration of Sufer in combination with sodium chloride solution, administration of Ferogel forte and injections of vitamin B12. Antibacterial therapy included the use of Bicillin intramuscularly, infusion of Genacef with sodium chloride solution, as well as local antiseptic therapy in the form of instillations of Okomistin and Iodim into the conjunctival sac.

To reduce inflammation and pain, the patient was prescribed Dexamethasone intravenously and Dexamolgin intramuscularly. Prevention of thrombosis and

correction of hemostasis was carried out with Xarelto, subcutaneous injections of Flenox and Magnicor taking. For the purpose of cardiac support, the patient received Digoxin, Klivas and Asparkam. Additionally, Renial and Forxigu were prescribed.

A comprehensive approach to treatment allowed for the correction of impaired hematological parameters, stabilization of the functional state of the cardiovascular system, control of the infectious process, and reduction of the risk of thromboembolic complications.

The therapy of concomitant diseases did not lead to changes in the local state: necrotic masses did not separate self-acting, they were firmly fixed to the underlying tissue. Considering the clinical situation, it was decided to perform necrectomy with subsequent free plastic surgery of the defect with autologous skin in 2 stages due to the extensiveness of the lesion area. In the first stage, which was carried out on 03.04.2023, necrotic masses were removed in the frontal, temporal and zygomatic areas (Fig. 4, 5).

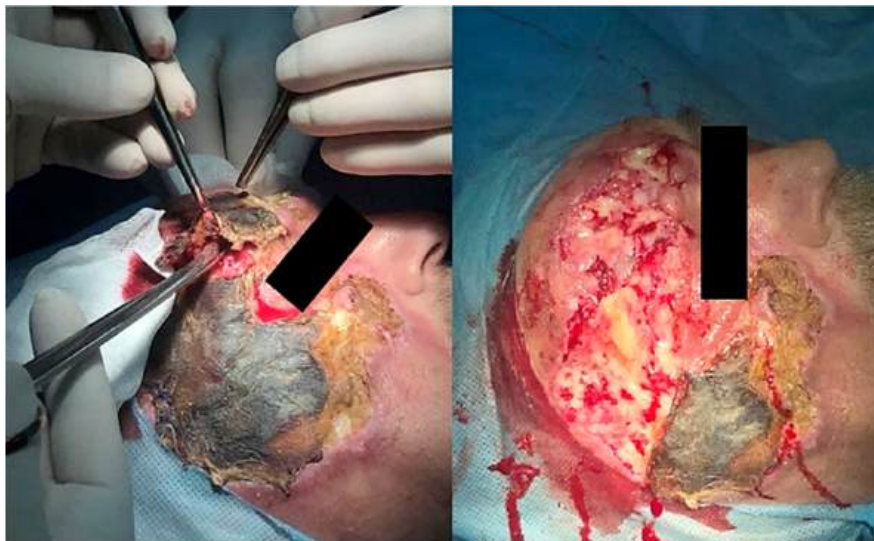


Fig. 4. Local state on day 1 after necrectomy

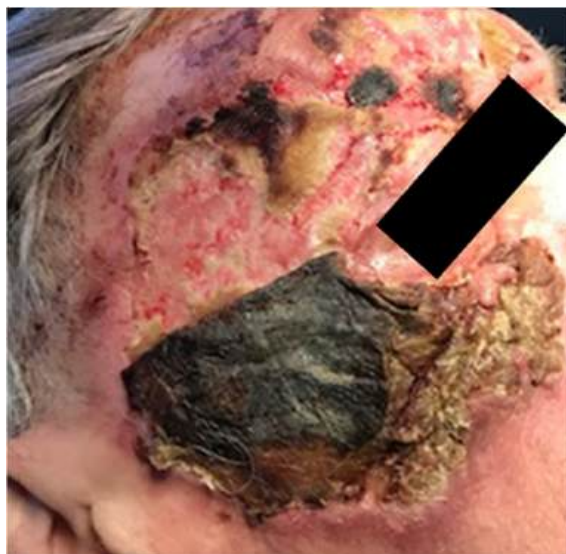
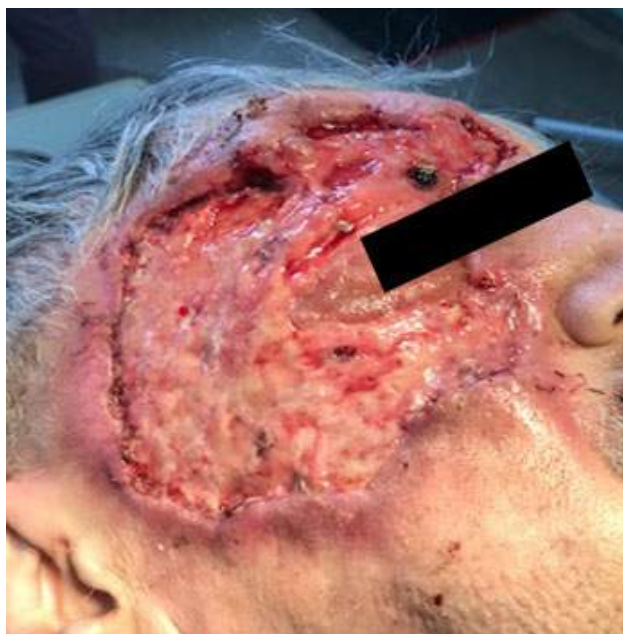
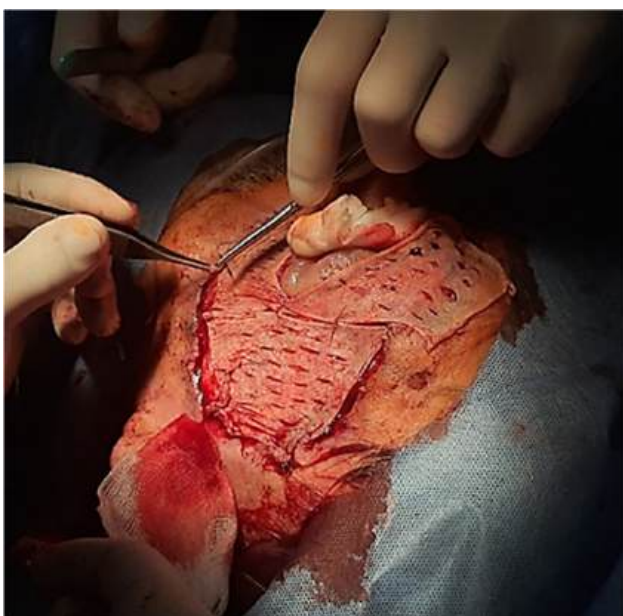
Fig. 5. Local state on day 5 after necrectomy

Given the positive dynamics of the healing process, the second stage of necrectomy was performed on day 6 after the first stage. The condition of the postoperative wound on the first day after the operation is presented in Fig. 6.

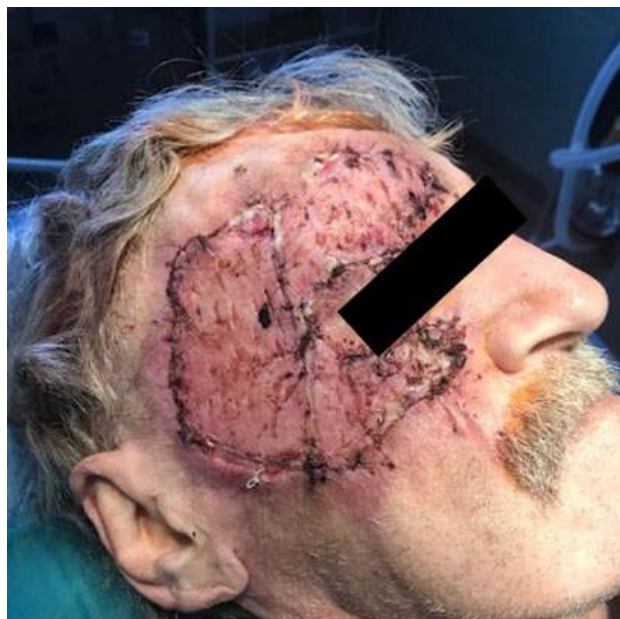

**Fig. 6. Condition of the postoperative wound on day 1 after surgery**

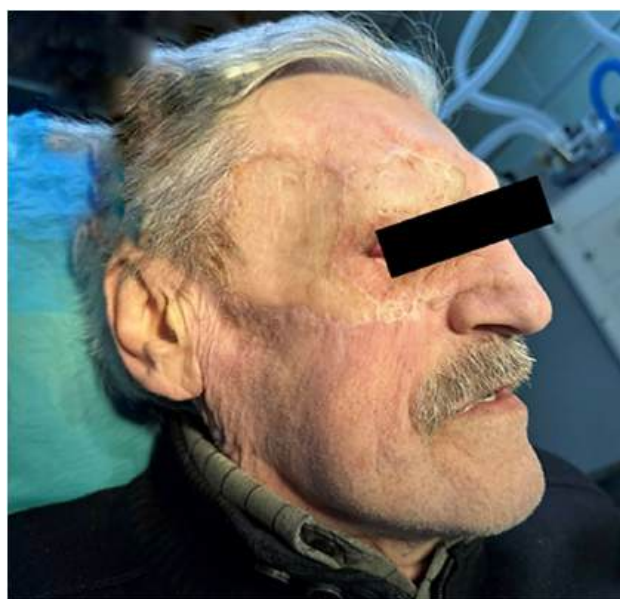The skin flap naturalized without complications (Fig. 7, 8, 9). The sutures were removed on day 8.



**Fig. 7. Free skin grafting onto the wound surface, which was taken from the anterior surface of the thigh (performed on 04.11.2023)**



**Fig. 8. The result of free skin plastic surgery**



**Fig. 9. Condition of the flap in a year**

#### RESULTS AND DISCUSSION

When discussing this clinical case, some of its features should be highlighted. It is evident that the skin necrosis resulted from a sudden disrupted local blood circulation. In COVID-19, the SARS-CoV-2 virus penetrates the vascular endothelium via angiotensin-converting enzyme 2 (ACE2), which is expressed not only in pulmonary endothelial cells but also in many other organs and tissues. This leads to vascular damage through coagulopathy and the development of an inflammatory response. Additionally, SARS-CoV-2 infection can trigger a cytokine storm due to excessive activation of

pro-inflammatory cytokines such as IL-1, IL-2, IL-6, TNF- $\alpha$ , and IFN- $\gamma$ , which may occur even in asymptomatic cases of COVID-19.

No less important is the role of blood coagulation. In dentistry in recent years, only a limited number of cases of maxillofacial tissue necrosis following COVID-19 have been reported, such as osteomyelitis of the upper jaw [13], oral cavity ulcers [14], and mucosal changes in the form of petechiae and reddish spots on the palate [14]. These findings indicate hypercoagulation and the occurrence of both arterial and venous thrombosis [8]. However, the pathogenesis of this condition remains incompletely understood. Multiple factors influence blood clotting, and several mechanisms have been identified to date. Endothelial damage appears to be the primary event in this chain of changes. The initial response to viral penetration involves activation of specific proteins that modulate the immune system, resulting in increased blood viscosity and a higher risk of thrombosis. A complex system of proteins circulates in the blood, detecting and neutralizing viruses, bacteria, and damaged cells. Under normal conditions, these proteins remove harmful elements without damaging the body. In the case of coronavirus infection, however, the protective system is highly activated and affects healthy tissues, particularly the endothelium, thereby increasing the likelihood of thrombosis.

Considering the size and localization of the defect in our patient, closure using local tissues was not possible. Therefore, the approach of free skin grafting following necrectomy was chosen. The postoperative period was uneventful.

#### CONCLUSIONS

1. Functional changes in the vasculature during COVID-19 lead to endothelial dysfunction, manifested by vasoconstriction, tissue ischemia, and coagulopathy, ultimately causing alterations in the maxillofacial tissues, which may result in necrosis.

2. The recommended treatment for such conditions is free skin grafting following necrectomy.

**Acknowledgments.** The authors wish to thank the colleagues from the Department of Dental Surgery at Ternopil Regional Clinical Hospital for their cooperation and support.

#### Contributions:

Nahirnyi Ya.P. – data curation, writing-original draft, writing-review & editing, administration, formal analysis;

Tverdokhlib N.O. – editing the article in english, methodology, conceptualization;

Stefaniv I.V. – resources, visualization.

**Funding.** This research received no external funding.

**Conflict of interests.** The authors declare no conflict of interest.

## REFERENCES

- Chakraborty SS, Malhotra A, Shah UA, Babu SR, Dandekar PB, Kumar DA, et al. Unusual case of a free anterolateral thigh flap partial necrosis in a COVID-19 positive young male following extremity reconstruction. *Chinese Journal of Traumatology*. 2023 Sep 1;26(05):308-10. doi: <https://doi.org/10.1016/j.cjtee.2023.02.002>
- Chung M, Bernheim A, Mei X, Zhang N, Huang M, Zeng X, et al. CT imaging features of 2019 novel coronavirus (2019-nCoV). *Radiology*. 2020 Apr;295(1):202-7. doi: <https://doi.org/10.1148/radiol.2020200230>
- Patel D, Louca C, Machuca Vargas C. Oral manifestations of long COVID and the views of healthcare professionals. *British Dental Journal*. 2024 Jan 26;236(2):111-6. doi: <https://doi.org/10.1038/s41415-023-6715-7>
- Lopez J, Mumtaz S, Amini A. Did the COVID-19 pandemic have an effect on oral cancer staging? A single-centre retrospective observational study. *British Dental Journal*. 2024 Feb;7:1-5. doi: <https://doi.org/10.1038/s41415-024-7056-x>
- Magro C, Mulvey JJ, Berlin D, Nuovo G, Salvatore S, Harp J, et al. Complement associated microvascular injury and thrombosis in the pathogenesis of severe COVID-19 infection: a report of five cases. *Translational Research*. 2020 Jun 1;220:1-3. doi: <https://doi.org/10.1016/j.trsl.2020.04.007>
- Prytula N, Fedotova I, Golbaum M. [The possibility of osteoporosis and avascular necrosis during the COVID-19 pandemic. A literature review]. *Orthopaedics traumatology and prosthetics*. 2022;1-2:118-22. Ukrainian. doi: <https://doi.org/10.15674/0030-598720221-2118-122>
- Palou EY, Ramos MA, Cherenfant E, Duarte A, Fuentes-Barahona IC, Zambrano LI, et al. COVID-19 associated rhino-orbital mucormycosis complicated by gangrenous and bone necrosis – a case report from Honduras. *Vaccines*. 2021 Jul 27;9(8):826. doi: <https://doi.org/10.3390/vaccines9080826>
- Mañón VA, Balandran S, Young S, Wong M, Melville JC. COVID-associated avascular necrosis of the maxilla – A rare, new side effect of COVID-19. *Journal of Oral and Maxillofacial Surgery*. 2022 Jul 1;80(7):1254-9. doi: <https://doi.org/10.1016/j.joms.2022.04.015>
- Burki T. Understanding variants of SARS-CoV-2. *Lancet (London, England)*. 2021 Feb 4;397(10273):462. doi: [https://doi.org/10.1016/S0140-6736\(21\)00298-1](https://doi.org/10.1016/S0140-6736(21)00298-1)
- Garcia-Beltran WF, Lam EC, Denis KS, Niti-do AD, Garcia ZH, Hauser BM, et al. Multiple SARS-CoV-2 variants escape neutralization by vaccine-induced humoral immunity. *Cell*. 2021 Apr 29;184(9):2372-83. doi: <https://doi.org/10.1016/j.cell.2021.03.013>

11. Farajzadeh S, Khalili M, Dehghani S, Babaie S, Fattah M, Abtahi-Naeini B. Top 10 acral skin manifestations associated with COVID-19: A scoping review. *Dermatologic therapy*. 2021 Nov;34(6):e15157.  
doi: <https://doi.org/10.1016/j.cell.2021.03.013>

12. Trotsky SM. [The role of SarS-CoV-2 genome mutation in the distribution of COVID-19 in Ukraine]. [dissertation]. Poltavskyi derzhavnyi medychnyi univertsytet. 2022. Ukrainian. Available from: <https://repository.pdmu.edu.ua/items/abedc949-fdbf-49e0-a435-0c2d0edfff02>

13. Kulkarni P, Beeraka D, Tanwar M, Kim U, Ganesan RM, Saini P. Frontal osteomyelitis post-COVID-19 associated mucormycosis. *Indian Journal of Ophthalmology*. 2023 Jul 1;71(7):2906-10.  
doi: [https://doi.org/10.4103/IJO.IJO\\_3117\\_22](https://doi.org/10.4103/IJO.IJO_3117_22)

14. Eghbali Zarch R, Hosseinzadeh P. COVID-19 from the perspective of dentists: a case report and brief review of more than 170 cases. *Dermatologic Therapy*. 2021 Jan;34(1):e14717.  
doi: <https://doi.org/10.1111/dth.14717>

Стаття надійшла до редакції 02.05.2025;  
затверджена до публікації 17.09.2025

